

Tadayuki Nishide*, Ikuko Kimura,
Natsuki Hayakawa, Yoko Yagi,
Etsuko Shibuya, Reiko Yasumura and
Nobuhisa Mizuki

Department of Ophthalmology and Visual Science,
Yokohama City University Graduate School of
Medicine

Dates: Received: 28 February, 2014; Accepted: 09
May, 2014; Published: 11 May, 2014

***Corresponding author:** Tadayuki Nishide,
Department of Ophthalmology and Visual Science,
Yokohama City University Graduate School of
Medicine, 3-9, Fukuura, Kanazawa-ku, Yokohama-
city, Kanagawa, post code: 236-0004, Japan, Tel:
+81-45-787-2683; Fax: +81-45-781-9755; E-mail:
nishide@abox3.so-net.ne.jp

www.peertechz.com

Keywords: Crocodile technique; Subretinal
proliferative tissue; Retinal detachment; A new
surgical technique; Vitreous forceps

Research Article

The “Crocodile Technique”: A New Ophthalmic Surgical Technique to Remove Subretinal Proliferative Tissue Associated with Retinal Detachment

Abstract

Purpose: To describe the “crocodile technique”, a new ophthalmic surgery technique for removing subretinal proliferative tissue (SPT) associated with retinal detachment.

Materials and Methods: Subjects were 21 patients who had retinal detachment with SPT. Their follow-up terms were all greater than 3 months. We undertook the crocodile technique during their subretinal surgery. The crocodile technique is a new ophthalmic technique for removing SPT using vitreous forceps, without using subretinal forceps, in small-gauge vitrectomy. After performing sufficient peripheral vitrectomy, a small intentional retinal tear was created above the SPT. The SPT was then stabilized while grasped by vitreous forceps in the subretinal space. The vitreous forceps were then rotated on their long axis, such that the SPT was rolled around the vitreous forceps in the subretinal space.

Results: The crocodile technique was successfully performed without enlarging the intentional retinal tear or creating new retinal tears, in all subjects. The retina was successfully reattached in all subjects, postoperative average visual acuity was improved after surgery, and postoperative re-detachment did not occur in any patients.

Conclusions: The crocodile technique can be performed without subretinal forceps. Using the technique, retinal detachment with SPT can be treated using vitreous forceps in small-gauge vitrectomy.

Abbreviations

SPT: Subretinal Proliferative Tissue; RPE: Retinal Pigment Epithelium

Introduction

Proliferative changes are observed in approximately 20% of retinal detachment cases for which surgery is deemed necessary [1]. In retinal detachments accompanied by proliferative changes, re-detachment following surgical repair often occurs because the subretinal proliferative tissue (SPT) creates a barrier between the retina and the retinal pigment epithelium (RPE), compromising retinal reattachment. Visual recovery in these cases is poorer than in cases with no proliferative changes [1,2]. Therefore, in cases of severe retinal detachment with SPT, SPT removal is necessary before retinopexy is performed. However, small-gauge subretinal forceps (23-gauge, 25-gauge, and 27-gauge) do not exist. If subretinal forceps are needed in small-gauge vitrectomy, it must be enlarged to a 20-gauge vitrectomy to accommodate them. Additionally, subretinal forceps have a curved tip and cannot be inserted from the small-gauge trocar.

In conventional SPT removal vitrectomy, an intentional retinal tear is created and the SPT is grasped below the retina using vitreous

forceps. In order to remove the SPT, it is lifted up, often enlarging the intentional retinal tear and the retinal detachment (Figure 1A, B). Herein, we present a new ophthalmic surgical technique that was used to remove SPT associated with retinal detachment, using small-gauge vitreous forceps. Using our new ophthalmic surgical technique, we can operate on the SPT in a small working space. Furthermore, we can substantially reduce the size of the SPT via a rolling action. Because the new ophthalmic surgery technique resembles the rotating behaviour that a crocodile exhibits while gripping a prey animal, we called it the crocodile technique.

Materials and Methods

In this study, we included patients who the excision of SPT was necessary for retinal reattachment using subretinal surgery. We excluded patients who simple vitrectomy or only preretinal surgery was performed. We undertook the crocodile technique to remove SPT using vitreous forceps in 21 patients (mean age 39.4 ± 18.6 years, 12 males and 9 females). We investigated preoperative LogMAR, postoperative LogMAR, and complications. The crocodile technique was performed as follows: 1. A small intentional retinal tear was created above the SPT, which was then grasped in the vitreous forceps (Figure 1A). 2. The vitreous forceps were stabilized and rotated around their long axis to roll the SPT around the forceps (Figure

IC). This motion did not require extensive intraocular or subretinal manipulation of the area. 3. We carefully removed the SPT outside the subretinal space. SPT removal did not require a great deal of force, and the intentional retinal tear did not enlarge (Figure 1D), because the crocodile technique can be performed through a small retinal tear with slow rolling forceps.

The crocodile technique requires rotation of gripped vitreous forceps. Some surgeons may initially find this technique somewhat difficult, but then quickly grow accustomed to it. In addition, the crocodile technique is easier to perform when a stabilizing attachment on the grip of the vitreous is used. The stabilizing attachment is made from a ring-shaped ultrasound (US) tip sleeve (Alcon, Tokyo, Japan), of the type commonly used in cataract surgery. The US sleeve is cut such that a 3 mm long cylinder remains (Figure 2A). The cylinder is then placed around the front part of ungripped forceps (Figure 2B). When performing the crocodile technique during surgery, the ring can be slipped around the vitreous forceps grip using the fingers, holding the forceps in a gripped position (Figure 2C). The surgeon can then perform the crocodile technique easily, by rotating the vitreous forceps.

Results

The retina was successfully reattached in all subjects. Preoperative mean LogMAR was 0.62 ± 0.34 , and postoperative mean LogMAR was 0.48 ± 0.35 (Table 1) (Mann-Whitney U test, $p < 0.01$). Visual acuity improved after surgery in all patients, and postoperative re-detachment did not occur. However, there was one instance

of an intraoperative peripheral retinal break, that occurred due to insufficient peripheral vitreous excision. This intraoperative complication was easily treated on that occasion. Two typical cases treated using the crocodile technique are described below.

Case 1

A 24-year-old female presented to our clinic with a posterior SPT, which inhibited retinopexy (Figure 3A). Her visual acuity was 20/50. A 23-gauge peripheral vitrectomy was performed before SPT removal. As the retina did not attach after the removal of preretinal proliferative tissue, even when gas exchange was performed, fluid exchange was performed again for SPT removal. We intentionally created a retinal tear above the SPT using diathermy. The SPT was then grasped with vitreous forceps in the subretinal space, and slowly rotated (Figure 3B). The rolled SPT was removed with a cutter, and withdrawn from below the retina (Figure 3C). Finally, the intentional retinal tear was used to drain subretinal fluid, as visually confirmed by retinal position monitoring (Figure 3D). Neither enlargement of the intentional retinal tear nor creation of new retinal tears were observed. The patient's visual acuity was 20/20 approximately 3 months after the surgery, at which point the retina remained attached.

Case 2

A 50-year-old female with a wide area of SPT below the retina presented to our clinic with a visual acuity of Counting Fingers. A 23-gauge peripheral vitrectomy was performed before SPT removal. As the retina did not attach after the removal of preretinal proliferative tissue, even when gas exchange was performed, fluid exchange was

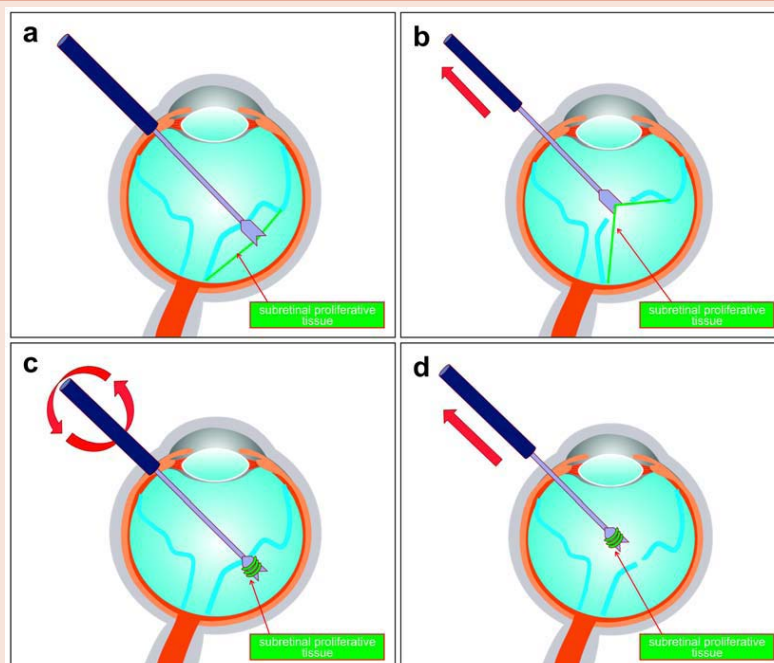


Figure 1: The movement of vitreous forceps during vitreous surgery for retinal detachment with subretinal proliferative tissue (SPT). A. The vitreous forceps grasp the SPT through an intentionally made retinal tear. **B.** Lifting the vitreous forceps while grasping the SPT causes it to be pulled upward, enlarging both the intentional tear and the retinal detachment. **C.** While grasping the SPT, the vitreous forceps are stabilized and rotated around their long axis. The SPT easily rolls onto the forceps. **D.** The rolled SPT is pulled above the retina without enlargement of the intentional retinal tear. Vitreous cutters are then used to remove the SPT intraocularly.




Figure 2: Cylinder generation and usage. A. A US sleeve of the type used in cataract surgeries (right), is cut to a cylinder of 4 mm in height (bottom), to use as a stabilizing attachment. B. The stabilizing attachment is fitted around vitreous forceps, as shown. C. The stabilizing attachment is moved around the grip of the vitreous forceps, which are stabilized while grasped.

Table 1: Patient outcomes.

Mean age (years)	39.4 ± 18.6
Preoperative mean LogMAR	0.62 ± 0.34
Postoperative mean LogMAR	0.48 ± 0.35
Successful reattachment rate	100%
Intraoperative complication rate (retinal tear: <i>n</i> = 1)	4.8%

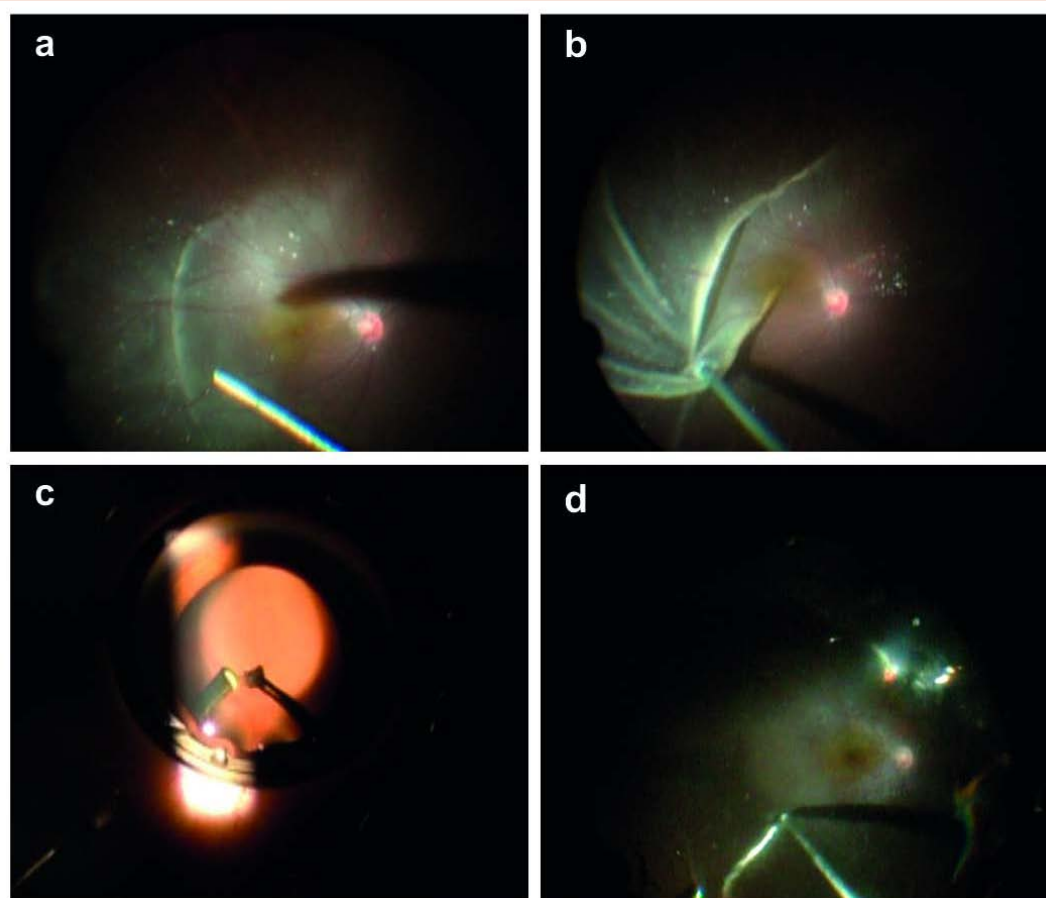


Figure 3: Images of case 1. A. Subretinal proliferative tissue (SPT) on the temporal side of the macula impeded reattachment of the retina. B. The SPT was grasped through an intentional tear, and slowly rotated around vitreous forceps. C. The SPT was rolled around the tip of the vitreous forceps and removed intraocularly, with a vitreous cutter. D. Subretinal fluid was drained through the small intentional tear that was created while performing the crocodile technique.

Citation: Nishide T, Kimura I, Hayakawa N, Yagi Y, Shibuya E, et al. (2014) The “Crocodile Technique”: A New Ophthalmic Surgical Technique to Remove Subretinal Proliferative Tissue Associated with Retinal Detachment. *J Clin Res Ophthalmol* 1: 101.

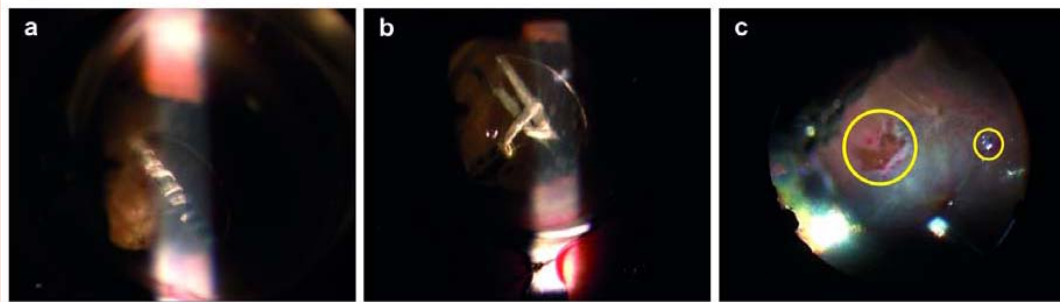


Figure 4: Images of case 2. **A.** Longsubretinal proliferative tissue (SPT) can be removed by rolling it around vitreous forceps. **B.** Vitreous forceps were rotated in the opposite direction to that which the SPT was initially rolled, because it was then removed intraocularly with a vitreous cutter. **C.** Case 2 fundus, post-air exchange. The retinal tear enlarged when SPT was removed via the conventional method (left yellow circle), but not when the crocodile technique was utilized (right yellow circle).

performed again for SPT removal. Because the SPT was so large, it had to be removed in two stages. The conventional method was used to complete the first stage of the surgery, and the crocodile technique was used to complete the second stage. The intentionally created retinal tear required enlargement for SPT removal when using the conventional method, but not when using the crocodile technique. Because the crocodile technique can roll even long SPT onto the vitreous forceps, the operative area remained small (Figure 4A), and intraocular removal was achieved with a vitreous cutter (Figure 4B). In addition to keeping the retinal tear small, there was no need to expand the scleral port or bring the cutter outside the eye. Subretinal fluid was then drained under visual guidance. The intentional tear made during the first stage of the surgery became large and irregularly shaped. The intentional tear created during the second stage however, in the course of performing the crocodile technique, remained small and regularly shaped because no enlargement was needed (Figure 4C). The patient's visual acuity was 20/200 approximately 12 months after the surgery, at which point the retina remained attached.

Discussion

The existence of SPT physically inhibits retinal reattachment, often resulting in postoperative re-detachment. Therefore, it is desirable to remove as much of the proliferative tissue as possible. The major advantage of our novel crocodile technique is that SPT can be removed without enlarging surgically created retinal tears, which often lead to postoperative visual field defects. Especially, although SPT shape was napkin-ring or bridge-like which impeding retinal reattachment, it was not necessary to make multiple intentional retinal hole or retinal incision using crocodile technique.

Stabilizing vitreous forceps with a stabilizing attachment allows the surgeon to concentrate solely on the rotational manipulation. This can easily be accomplished with grasped vitreous forceps, if the forceps have a 360-degree grip. It is extremely important to only rotate the forceps while they are gripped. When using chandelier lighting during vitrectomy [3], the vitreous forceps can be rotated without using a stabilizing attachment, when gripping the forceps with both hands.

Removal of SPT with conventional methods requires a sudden upward force on the retina, which can create new tears at the points

of SPT attachment to the retina. We did not observe such problems with the crocodile technique, which rolls the SPT onto vitreous forceps using a small, fixed amount of rotational force. Although part of the SPT sometimes remained, it did not pose a problem when retinopexy was performed immediately following gas exchange. When performing the crocodile technique, it is important to first perform sufficient peripheral vitrectomy, particularly at the site of the rotation port. If this is not done, the peripheral vitreous body may be rolled onto the vitreous forceps when they are rotated, creating new peripheral retinal tears. These tears are often large, making retinopexy difficult [4].

The crocodile technique should not be used for a proliferative membrane film that spreads out below the retina, or for thick bands of proliferative tissue. When moving these types of SPT into the preretinal space, the intentional retinal tear must be enlarged. When multiple thin bands of SPT are present, the crocodile technique can be performed repeatedly without tear enlargement, prior to retinopexy.

Subretinal forceps may be used to perform the crocodile technique in 20-gauge vitreous surgery, particularly to remove SPT situated away from the intentional retinal tear. However, caution is required because lifting the SPT above the retina may enlarge the intentional tear. Subretinal proliferative tissue can also be successfully removed in small-gauge vitrectomy using our novel crocodile technique. This can be accomplished with vitreous forceps while performing retinopexy, without enlarging intentionally created retinal tears. Due to these features, the crocodile technique is useful for the removal of severe SPT, while minimizing retinal damage.

Author Contributions

Design of the study, T.N., I.K., N.H.; conducting the study, T.N., I.K., N.H., E.S., R.Y., N.M.; data analysis, T.N., N.H., Y.Y., E.S.; manuscript preparation, T.N., N.H., E.S.

References

1. Heimann H1, Zou X, Jandek C, Kellner U, Bechrakis NE, et al. (2006) Primary vitrectomy for rhegmatogenous retinal detachment: an analysis of 512 cases. *Graefes Arch Clin Exp Ophthalmol* 244: 69-78.
2. Scott IU1, Flynn HW Jr, Murray TG, Feuer WJ, Perfluoron study group (2003) Outcomes of surgery for retinal detachment associated with proliferative



- vitreoretinopathy using perfluoro-n-octane: a multicenter study. Am J Ophthalmol 136: 454-463.
3. Eckardt C, Eckert T, Eckardt U (2008) 27-gauge Twinlight chandelier illumination system for bimanual transconjunctival vitrectomy. Retina 28: 518-519.
 4. Scott IU1, Murray TG, Flynn HW Jr, Feuer WJ, Schiffman JC, et al. (2002) Outcomes and complications associated with giant retinal tear management using perfluoro-n-octane. Ophthalmology 109: 1828-1833.

Copyright: © 2014 Nishide T, et al. This is an open-access article distributed under the terms of the Creative Commons Attribution License, which permits unrestricted use, distribution, and reproduction in any medium, provided the original author and source are credited.

Citation: Nishide T, Kimura I, Hayakawa N, Yagi Y, Shibuya E, et al. (2014) The "Crocodile Technique": A New Ophthalmic Surgical Technique to Remove Subretinal Proliferative Tissue Associated with Retinal Detachment. J Clin Res Ophthalmol 1: 101.