

TRANSCONJUNCTIVAL NONVITRECTOMIZING VITREOUS SURGERY VERSUS 25-GAUGE VITRECTOMY IN PATIENTS WITH EPIRETINAL MEMBRANE

A Prospective Randomized Study

MICHELE REIBALDI, MD, PhD,* ANTONIO LONGO, MD, PhD,* TERESIO AVITABILE, MD,*
VINCENZA BONFIGLIO, MD,* MARIO D. TORO, MD,* ANDREA RUSSO, MD,*
FRANCESCA VITI, MD,† MICHELE NICOLAI, MD,† ANDREA SAITTA, MD,†
ALFONSO GIOVANNINI, MD,† CESARE MARIOTTI, MD†

Purpose: To compare the clinical outcomes and the rate of complications of 27-gauge transconjunctival nonvitrectomizing vitreous surgery (NVS) and of 25-gauge transconjunctival sutureless vitrectomy surgery for idiopathic epiretinal membrane removal.

Methods: In this prospective randomized study, 83 phakic eyes of 83 consecutive patients with an idiopathic epiretinal membrane were randomized to receive 27-gauge NVS (NVS-group) or 25-gauge vitrectomy (Standard-group). Main outcome measures were best-corrected visual acuity, central retinal thickness, nuclear density units' changes, and rate of complications.

Results: Thirty-nine eyes of the Standard-group and 40 of the NVS-group were considered in final analysis. Mean best-corrected visual acuity improved significantly in both groups, with a significant better result at 12 months in NVS-group ($P = 0.039$; *t*-test). Central retinal thickness decreased significantly in both groups ($P < 0.001$, *Tukey* test), without significant difference between the two groups at any time point. At 12 months, nuclear density increased significantly in the Standard-group (analysis of variance, $P < 0.001$), and it did not change in the NVS-group (analysis of variance, $P = 0.537$). Epiretinal membrane recurred in 5.1% of eyes in the Standard-group and in 7.5% of eyes in the NVS-group (Fisher's exact test, $P = 1.000$).

Conclusion: The 27-gauge NVS is an effective surgical procedure in eyes with epiretinal membrane and it induces less progression of nuclear sclerosis than 25-gauge vitrectomy.

RETINA 0:1–7, 2014

Epiretinal membrane (ERM) removal has become a standard technique in vitreoretinal surgery. Vitrectomy is currently being performed in eyes with relatively good visual acuity, because the threshold

for surgery for ERM has decreased due to improvements in surgical techniques.¹

Recent introduction of transconjunctival small-gauge vitrectomy surgery has provided potential advantages over traditional 20-gauge surgery, including faster wound healing, less conjunctival scarring, decreased operating time, improved patient comfort, and less postoperative inflammation with early visual recovery.^{2,3}

However, despite continuous advances to improve safety of vitrectomy for macular diseases, cataract progression and iatrogenic peripheral retinal breaks

From the *Eye Clinic, University of Catania, Catania, Italy; and †Eye Clinic, Azienda Ospedaliero Universitaria Ospedali Riuniti Umberto I-GM Lancisi-G Salesi di Ancona, University of Marche, Ancona, Italy.

None of the authors have any financial/conflicting interests to disclose.

Reprint requests: Antonio Longo, MD, PhD, Eye Clinic, University of Catania, Via Santa Sofia 78, 95123 Catania, Italy; e-mail: ant-longo@libero.it

remain common postoperative complications even with small-gauge instrumentation.⁴

Nonvitrectomizing vitreous surgery (NVS) has been proposed as an alternative surgical procedure to remove ERM without removing the vitreous.⁵ In a prospective study, it has been shown that ERM can be effectively removed by NVS, without inducing a progression of nuclear sclerosis; at a long term, the recurrence rate of ERM was higher than that reported with conventional vitrectomy.⁶

No study to date has compared vitrectomy with NVS in terms of efficacy and rate of side effects. The purpose of this study was to compare the functional and anatomical outcomes, and the rate of complications between standard 25-gauge vitrectomy and NVS in patients with idiopathic ERM.

Materials and Methods

Subjects

This is a prospective randomized study. All consecutive phakic patients with an idiopathic ERM evaluated at the Department of Ophthalmology of the University of Ancona (Italy), between May 2010 and January 2012, were randomized to receive 25-gauge standard vitrectomy (Standard-group) or 27-gauge NVS (NVS-group). Only eyes with a minimal follow-up of 12 months were included in the analysis. If a patient had surgery in both eyes, the first eye that received surgery was included in the study.

The study was approved by the institutional ethics committee, and all patients signed informed consents after the aim and the possible risks of the study were fully explained.

Inclusion criteria were the presence of an idiopathic ERM within the temporal arcades clearly visible through biomicroscopy, clear vitreous, best-corrected visual acuity (BCVA) >0.2 logMAR, metamorphopsia, absent-to-moderate cataract (Grade 0.0–2.0 of Thompson classification).⁷

Patients were excluded if they had secondary ERM, preoperative retinal breaks, previous ocular surgery, myopia with an axial length >26 mm, amblyopia, diabetic retinopathy, retinal vascular occlusion, macular disorders, corneal disorders, other ocular pathologic features that could have interfered with functional results, the prolonged use of topical or systemic corticosteroids, or any other known condition that may have altered the rate of cataract progression after vitrectomy.

After inclusion into the study, the participants were randomly assigned 1:1 to either the Standard-group or to the NVS-group using a computer-generated randomization list.

Preoperatively and at Day 1, Weeks 1 and 2, and Months 1, 6, and 12 after surgery, each patient underwent a complete evaluation, with BCVA determination, anterior segment examination, intraocular pressure (IOP) evaluation, dilated fundus examination using indirect ophthalmoscopy with scleral depression, and spectral domain optical coherence tomography (OCT).

In a database, the following parameters were collected: patient demographics, BCVA, preoperative lens status, IOP, central retinal thickness, axial length, the number of intraoperative and postoperative iatrogenic retinal breaks, the incidence of postoperative, rhegmatogenous retinal detachment, and other surgery-related complications.

Best-corrected visual acuity was measured using the Early Treatment Diabetic Retinopathy Study charts at a 4-m distance by a single, well-trained experienced ophthalmologist (A.S.) who was masked to the study. Vision results were quantified in logMAR.

The nuclear density was assessed by digital Scheimpflug lens photography at baseline and at 1, 6, and 12 months after surgery. Lens images were taken and analyzed by the anterior eye segment analysis system (NIDEK EAS-1000; NIDEK, Gama-gori, Japan). All lens images were taken by the same observer (M.N.), masked to the type of surgery performed, after pupillary dilatation at the same settings, as described by Sawa et al.^{6,8} The opacification value of the nuclear region was expressed in nuclear density units (NDUs).

Intraocular pressure was measured by Goldmann applanation tonometry (mean IOP of 3 consecutive measurements was taken). We defined “hypotony” as an IOP ≤5 mmHg.

Axial length was assessed preoperatively by A-scan ultrasound examination (Cinescan S “HF”; Quantel Medical, Clermont-Ferrand, France).

Spectral domain OCT images were obtained with the Spectralis OCT version 5.1.3.0 (Heidelberg Engineering, Heidelberg, Germany) with Heidelberg Eye Explorer version 1.6.2.0 (Heidelberg Engineering) to assess the central retinal thickness and foveal morphology. All OCT examinations were carried out by a certified operator (F.V.). In OCT images, ERM was defined as thin highly reflective bands either anterior to the neurosensory retina with focal areas of macular attachments or globally adherent to the retinal surface.⁹ Radial, 20° 6-line scans centered on the fovea were obtained for each eye. More than 25 scans were averaged for each measurement. Two masked expert investigators (M.T., A.L.) interpreted the spectral domain OCT images. When there was disagreement, a third (M.R.) investigator was consulted for the final decision.

Peripheral retinal breaks were defined as definite retinal breaks located between the midperiphery and the ora serrata.¹⁰ Indeterminate retinal lesions that resembled retinal breaks were not included.

Surgical Techniques

All patients underwent surgery by the same surgeon (C.M.), after local anesthesia. The periocular area was cleaned with povidone-iodine 7%; the ocular surface was sterilized by administering povidone-iodine 5% eye drops in the conjunctival fornix.

In the NVS-group, the conjunctiva was displaced and a scleral tunnel was created by introducing a 25-gauge trocar (Synergetics USA, Inc) after measuring 4 mm from the limbus in the inferotemporal quadrant in the left eye and on the inferonasal side in the right eye to avoid obscuring the macula with the instrument. The infusion line was then connected to the light source without opening the infusion. After displacing the conjunctiva, the second 25-gauge trocar was positioned in the superotemporal quadrant in the right eye, or in the superonasal side in the left eye. This trocar was inserted so as to provide optimal access to the macula, thus minimizing flexion of the 25-gauge equipment. A contact lens was used to visualize the posterior pole. The direction of the illumination was adjusted with the left hand to gain a better view of the macula. A pair of 27-gauge disposable forceps (Synergetics USA, Inc, O'Fallon, MO) was introduced with the right hand, minimizing movements through the vitreous. Peeling of the epimacular tissue was performed with forceps, without the use of dyes. At the end of the procedure, the ERM was removed from the eye, and a complete examination of the peripheral retina was performed using the Resight 700 (Carl Zeiss Meditec AG, Jena, Germany) wide-angle viewing system or the Binocular Indirect Ophthalmoscope wide-angle viewing system (BIOM; Oculus Inc, Wetzlar, Germany). When a complete ERM removal was not possible, standard vitrectomy was performed and the patient was excluded from the study.

In the Standard-group, vitrectomy was performed with 25-gauge instruments and the Constellation vision system (UHS Alcon Constellation; Alcon Laboratories, Inc, Fort Worth, TX) with an ultrahigh-speed cut rate (5,000 cuts per minute), a duty circle control, and up to 600 mmHg of linear aspiration. The 25-gauge suturless trocar system by Alcon Laboratories, Inc was used for microincisions. All cases were performed using the Resight 700 wide-angle viewing system or the BIOM wide-angle viewing system; peeling of ERM was performed under visualization of the posterior pole by a contact lens.

Sclerotomies were placed 4 mm posterior to the limbus and were performed in a 30°-angled fashion, parallel to the limbus. The infusion cannula was positioned in the inferotemporal quadrant, and superotemporal and superonasal sclerotomies were conducted near the 10- and 2-o'clock meridians. Vitrectomy started shaving the anterior vitreous. Core vitrectomy was then performed and, if not already present, a posterior vitreous detachment was induced.

Epiretinal membrane peeling was carried out using end-gripping forceps, without the use of dyes. After peeling, in all cases, the vitreous was removed up to the far periphery under fluid infusion.

In both groups, before the conclusion of surgical treatments, the peripheral retina was examined using a wide-angle viewing system. All retinal breaks that were detected during surgery were treated through endolaser photocoagulation.

At the end of the procedure, the cannulas were removed and each sclerotomy site was gently pressed with a cotton swab and carefully inspected for leakage. If the sclerotomy site was found to be leaking after this procedure, it was sutured with a single 9-0 vicryl stitch. The eye was dressed with a standard non-pressure ocular bandage. Topical antibiotics and steroids were prescribed for 1 month and oral antibiotics for 5 days postoperatively.

Statistical Analysis

The sample size (at least 25 eyes for each group) was determined from the results of previous studies and our preliminary data to detect, with an alpha of 0.05 and a 90% power (1-tailed), a 0.15 logMAR increase in visual acuity.

In each group, the mean values of BCVA, central retinal thickness, and NDUs detected before and at 1, 6, and 12 months after treatment were compared by analysis of variance (ANOVA); if significant, multiple comparisons were performed with the *Tukey HSD* (honest significant differences) test. Mean values detected in the two groups at each time point were compared by *t*-test. The rate of complications between the two groups was analyzed using the Fisher's exact test. Values of $P < 0.05$ were considered statistically significant. Statistical analysis was conducted using the SPSS 11.5.1 for Windows soft package (SPSS, Inc, Chicago, IL).

Results

Of the overall 133 eyes with ERM, 50 did not meet the inclusion criteria. The remaining 83 eyes were enrolled and randomized to receive standard

vitrectomy (41 eyes) and NVS (42 eyes); in the first group, 1 patient was lost to follow-up, and 1 developed a retinal detachment, and underwent 25-gauge vitrectomy with silicone oil tamponade; both were excluded from analysis. In the second group, NVS was converted to standard vitrectomy in 2 eyes because it was not possible to completely remove the ERM; therefore, in the final analysis were evaluated 39 eyes of the Standard-group and 40 eyes of NVS-group, as showed in the flow diagram (Figure 1). At baseline, there was no significant difference in the demographics and clinical data between the groups (Table 1).

Best-corrected Visual Acuity

At baseline, the mean ± standard deviation BCVA (Snellen units) was 0.41 ± 0.13 logMAR (20/51) in the Standard-group and 0.39 ± 0.16 logMAR (20/49) in the NVS-group (*P* = 0.554; *t*-test). Best-corrected visual acuity of both groups significantly improved after surgery (ANOVA, *P* ≤ 0.001): at 12 months, mean BCVA was 0.27 ± 0.20 logMAR (20/37) in the Standard-group and 0.18 ± 0.15 logMAR (20/30) in the NVS-group, (both *P* < 0.001 vs. baseline, Tukey HSD test), with a statistically significant difference between 2 groups (*P* = 0.039; *t*-test) (Table 2).

Central Retinal Thickness

At 12 months after treatment, the mean ± standard deviation central retinal thickness was 275 ± 57 μm in the Standard-group and 289 ± 68 μm in the NVS-group (Table 2), significantly lower in both groups than the mean preoperative values at all time points (*P* < 0.001, Tukey HSD test), without significant difference between the 2 groups (*P* = 0.338; *t*-test).

Progression in Lens Opacity

At baseline, the mean ± standard deviation NDUs was 69 ± 14 in the Standard-group and 70 ± 15 in the NVS-group (*P* = 0.700; *t*-test). Statistical analysis by repeated measures ANOVA showed that the mean NDUs change significantly in the Standard-group (ANOVA, *P* < 0.001), with a significant increase versus baseline at 12 months (*P* < 0.001, Tukey HSD test); no changes were found in the NVS-group (ANOVA, *P* = 0.537); a higher NDU value was seen at 12 months in the Standard-group (*P* = 0.001; *t*-test) (Table 2).

Epiretinal Membrane Recurrence

Removal of the ERM was defined clinically and by OCT. At 12 months, an ERM recurrence was found in

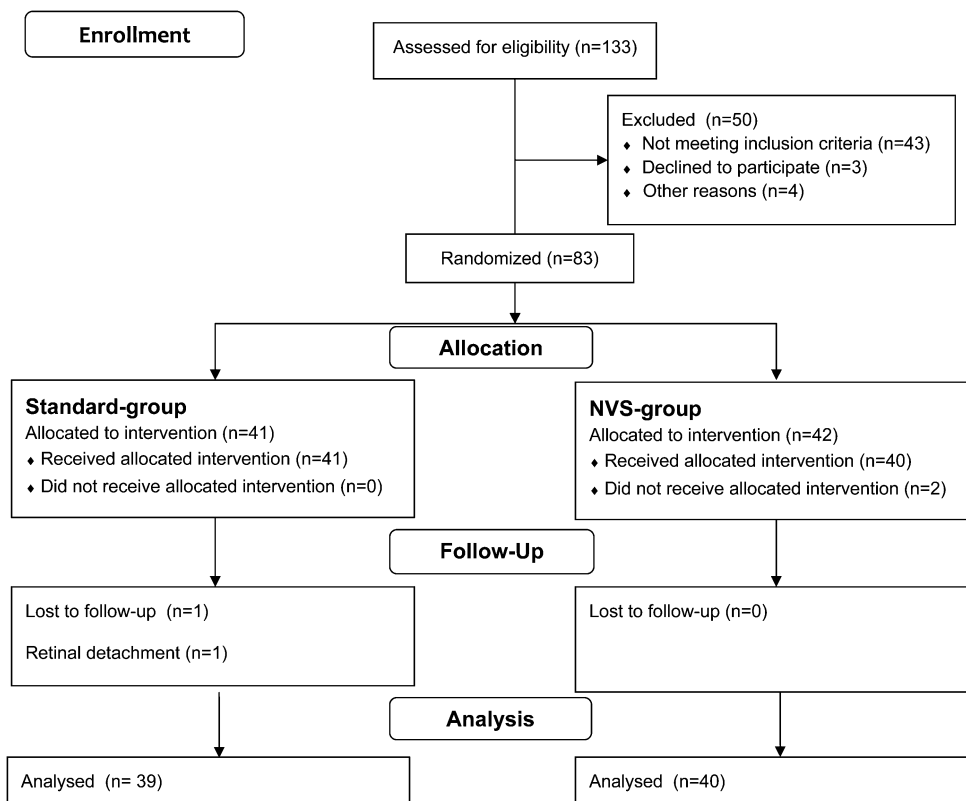


Fig. 1. Flow diagram of the study that shows progress through the four phases (enrollment, allocation, follow-up, and analysis) of the parallel randomization of the Standard-group and the NVS-group.

Table 1. Baseline Demographics and Clinical Characteristics of Eyes With ERM Treated by Standard 25-Gauge Vitrectomy (Standard-Group) or 27-Gauge Transconjunctival NVS-Group

	Standard-Group (n = 39)	NVS-Group (n = 40)	P*
Mean age (years) ± SD	66 ± 6	64 ± 6	0.143
Mean BCVA (logMAR) ± SD (Snellen Units)	0.41 ± 0.13 (20/51)	0.39 ± 0.16 (20/49)	0.544
Mean CRT (μm) ± SD	457 ± 92	438 ± 98	0.377
Mean NDUs (n°) ± SD	69 ± 14	70 ± 15	0.760
Mean IOP (mmHg) ± SD	13.2 ± 4.1	12.9 ± 3.7	0.734
Mean AL (mm) ± SD	23.9 ± 1.2	24.1 ± 1.1	0.442

*t-test.

AL, axial length; CRT, central retinal thickness; SD, standard deviation.

2 of 39 eyes (5.1%) in the Standard-group and in the 3 of 40 eyes (7.5%) in the NVS-group, without a significant difference between the 2 groups ($P = 1.000$; Fisher's exact test).

Complications

Complications are shown in Table 3. Retinal breaks were found, in the Standard-group, intraoperatively in 2 of 39 eyes (5.1%) and postoperatively in 1 eye

(2.6%); in the NVS-group, no eyes (0%) had intraoperative or postoperative retinal breaks. Hypotony was recorded at 1 day postoperative in 2 of 39 eyes (5.1%) of the Standard-group and in 1 of 40 eyes (2.5%) of the NVS-group; the IOP normalized in all eyes by the first postoperative day.

Floater were reported during the immediate postoperative period in 2 of 39 eyes (5.1%) in the Standard-group and in 8 of 40 eyes (20%) in the NVS-group ($P = 0.087$, Fisher's exact test);

Table 2. Best-corrected Visual Acuity, Central Foveal Thickness, and NDUs at Baseline, 1, 6, and 12 Months After Surgery in Eyes With ERM Treated by Standard 25-Gauge Vitrectomy (Standard-Group) or 27-Gauge Transconjunctival NVS-Group

	Standard-Group (n = 39)	NVS-Group (n = 40)	P*
BCVA (logMAR) (Mean ± SD) (Snellen Units)			
Baseline	0.41 ± 0.13 (20/51)	0.39 ± 0.16 (20/49)	0.554
1 month	0.33 ± 0.15 (20/43)	0.31 ± 0.18 (20/41)	0.594
6 months	0.30 ± 0.12 (20/40)	0.26 ± 0.13 (20/36)	0.115
12 months	0.27 ± 0.20 (20/37)	0.18 ± 0.15 (20/30)	0.039
P†	0.001	<0.001	—
P‡	0.016§, <0.001¶	0.001§, <0.001¶	—
CRT (μm) (Mean ± SD)			
Baseline	457 ± 92	452 ± 98	0.778
1 month	321 ± 87	320 ± 94	0.933
6 months	304 ± 90	298 ± 82	0.768
12 months	275 ± 57	289 ± 68	0.338
P†	<0.001	<0.001	—
P‡	<0.001§¶**	<0.001§¶**	—
NDUs (n°) (Mean ± SD)			
Baseline	69 ± 14	70 ± 15	0.700
1 month	71 ± 16	70 ± 13	0.779
6 months	77 ± 15	73 ± 15	0.175
12 months	87 ± 18	74 ± 16	0.001
P†	<0.001	0.537	—
P‡	<0.001¶	—	—

*t-test.

†ANOVA.

‡Tukey HSD (honest significant differences) test.

§Six months versus baseline.

¶Twelve months versus baseline.

**One month versus baseline.

CRT, central retinal thickness; SD, standard deviation.

Table 3. Incidence of Complications in Eyes With ERM Treated by Standard 25-Gauge Vitrectomy (Standard-Group) or 27-Gauge Transconjunctival NVS-Group

	Standard-Group (n = 39), n (%)	NVS-Group (n = 40), n (%)	P*
Retinal breaks intraoperative	2 (5.1)	0 (0)	0.241
Retinal breaks postoperative	1 (2.6)	0 (0)	0.494
Bleeding	3 (7.6)	2 (5)	0.675
Hypotony	2 (5.1)	1 (2.5)	0.615
Early floaters	2 (5.1)	8 (20)	0.087
Persistent floaters	2 (5.1)	5 (12.5)	0.432
Clinical cystoid macular edema	1 (2.6)	0 (0)	0.494

*Fisher's exact test.

persistence of floaters at 12 months was reported in 2 eyes of 39 (5.1%) in the Standard-group and in 5 of 40 eyes (12.5%) in the NVS-group ($P = 0.432$, Fisher's exact test).

Discussion

Our study shows that 27-gauge transconjunctival NVS is effective in the treatment of ERM, by improving visual acuity significantly without serious intraoperative and postoperative complications and inducing less progression of nuclear sclerosis compared with 25-gauge vitrectomy.

Nonvitrectomizing vitreous surgery, a surgical procedure aiming to remove ERM without removing the vitreous, has been described for the first time by Charles.¹¹ Saito et al⁵ showed that this technique is safe and efficient to remove ERM and prevent the development or progression of nuclear sclerosis with a low incidence of recurrence of ERM. Sawa et al⁶ showed, after a mean follow-up of 6 years after NVS, that the median visual acuity improved from 20/50 to 20/25, with an improvement or stabilization within 2 lines in 96.7% of eyes; 3 eyes received an additional vitrectomy and cataract surgery. After standard vitrectomy, Kim et al (20- or 23-gauge) reported an increase in BCVA from 0.49 ± 0.23 logMAR to 0.15 ± 0.19 logMAR at 2 years; Kim et al^{12,13} reported an increase of >2 Snellen lines in 77% of the eyes at 12 months. Our study shows a statistically significant improvement of mean BCVA in both groups, with better results at 12 months after NVS (Standard-group: 0.27 logMAR [20/37]; NVS-group: 0.18 logMAR [20/30]). Lower BCVA values detected in the Standard-group could be explained by the increase of nuclear sclerosis (mean NDUs) detected in this group; however, no eye developed a cataract requiring surgery during follow-up. In NVS-group, mean NDUs were unchanged, in agreement with Sawa et al,⁸ which found no progression

of nuclear sclerosis after NVS (no difference between the operated and the fellow untreated eye at 1 and 6 years).

As recently demonstrated, cataract occurs in most cases at 6 months after vitrectomy, regardless the caliber of instrument.⁴ It is well established that vitrectomy surgery causes an acceleration of nuclear sclerotic cataract formation, with a mechanism not completely understood. One possible hypothesis is that in the absence of the vitreous gel, molecular oxygen from the retinal vasculature reaches the lens and promotes oxidative damage of the lens nucleus, an increase in light scattering, and nuclear sclerotic cataract.¹⁴

In our study, at 12 months, ERM recurred in 5.1% of eyes in the Standard-group and in 7.5% of eyes in the NVS-group without a significant difference between the 2 techniques. Sawa et al⁶ reported a recurrence in 4 of 41 eyes (9.75%) after a mean of 22 months, and at a long term (6 years of follow-up), in 33% of the treated eyes. With standard vitrectomy, recurrence of ERM ranged from 4% to 12%.^{15–18}

Some authors advocate that removal of the internal limiting membrane (ILM) can reduce the recurrence rate, because the ILM can act as a scaffold for glial proliferation after successful removal of the ERM.^{18,19} However, long-term effects of ILM removal are unknown, and mechanical injury to the neurosensory retina during ILM peeling has been a concern.^{20,21} In our study, punctate retinal hemorrhages were observed usually during ERM peeling also in the NVS-group, suggesting that the ILM has been removed together with the ERM.

Furthermore, to reduce the ERM recurrence after NVS, in this study, we converted to standard small-gauge surgical procedures in case of incomplete removal of the ERM during NVS.

Although the recent evolution of vitreoretinal surgical techniques, the incidence of retinal breaks has been reported in small-incision vitrectomy up to 15.8% of the eyes.^{10,22–32} After NVS, Saito et al⁵

reported no retinal breaks during the follow-up period. In our study, similar incidence of retinal breaks in two groups suggests that NVS does not negatively affect the retina.

One of the main disadvantages of the NVS technique is the presence of floaters, as shown by Saito et al,⁵ which may be very bothersome to some patients. In our study, postoperative incidence of floaters was of 20% in eyes treated by NVS but spontaneously regressed in many of them, with a final rate of 12%, slightly greater than that after standard vitrectomy.

The main limitation of our study is the short follow-up: at a long term, increased recurrence of ERM and changes in nuclear density could occur.

In conclusion, 27-gauge NVS is effective in the treatment of ERM improving visual acuity, not increasing the rate of complications, inducing a less progression of nuclear sclerosis with respect to 25-gauge vitrectomy; moreover, it is possible to convert to a standard procedure in case of incomplete removal of the ERM.

Key words: cataract, idiopathic epiretinal membrane, nonvitrectomizing surgery, retinal break, vitrectomy.

References

1. Reibaldi M, Rizzo S, Avitabile T, et al. Iatrogenic retinal breaks in 25-gauge vitrectomy under air compared with the standard 25-gauge system for macular diseases. *Retina* 2014;34:1617–1622.
2. Spirm MJ. Comparison of 25, 23 and 20-gauge vitrectomy. *Curr Opin Ophthalmol* 2009;20:195–199.
3. Thompson JT. Advantages and limitations of small gauge vitrectomy. *Surv Ophthalmol* 2011;56:162–172.
4. Almony A, Holekamp NM, Bai F, et al. Small-gauge vitrectomy does not protect against nuclear sclerotic cataract. *Retina* 2012;32:499–505.
5. Saito Y, Lewis JM, Park I, et al. Nonvitrectomizing vitreous surgery: a strategy to prevent postoperative nuclear sclerosis. *Ophthalmology* 1999;106:1541–1545.
6. Sawa M, Ohji M, Kusaka S, et al. Nonvitrectomizing vitreous surgery for epiretinal membrane. *Ophthalmology* 2005;112:1402–1408.
7. Thompson JT, Glaser BM, Sjaarda RN, Murphy RP. Progression of nuclear sclerosis and long-term visual results of vitrectomy with transforming growth factor beta-2 for macular holes. *Am J Ophthalmol* 1995;119:48–54.
8. Sawa M, Saito Y, Hayashi A, et al. Assessment of nuclear sclerosis after nonvitrectomizing vitreous surgery. *Am J Ophthalmol* 2001;132:356–362.
9. Duan XR, Liang YB, Friedman DS, et al. Prevalence and associations of epiretinal membranes in a rural Chinese adult population: the Handan Eye Study. *Invest Ophthalmol Vis Sci* 2009;50:2018–2023.
10. Tan HS, Mura M, de Smet MD. Iatrogenic retinal breaks in 25-gauge macular surgery. *Am J Ophthalmol* 2009;148:427–430.
11. Charles S. *Vitreous Microsurgery*. 2nd ed. Baltimore, MD: Williams & Wilkins; 1987: 153–157.
12. Kim J, Rhee KM, Woo SJ, et al. Long-term temporal changes of macular thickness and visual outcome after vitrectomy for idiopathic epiretinal membrane. *Am J Ophthalmol* 2010;150:701–709.
13. Kim JH, Kim YM, Chung EJ, et al. Structural and functional predictors of visual outcome of epiretinal membrane surgery. *Am J Ophthalmol* 2012;53:103–110.
14. Holekamp NM, Shui YB, Beebe DC. Vitrectomy surgery increases oxygen exposure to the lens: a possible mechanism for nuclear cataract formation. *Am J Ophthalmol* 2005;139:302–310.
15. de Bustros S, Thompson JT, Michels RG, et al. Vitrectomy for idiopathic epiretinal membranes causing macular pucker. *Br J Ophthalmol* 1988;72:692–695.
16. Grewing R, Mester U. Results of surgery for epiretinal membranes and their recurrences. *Br J Ophthalmol* 1996;80:323–326.
17. Margherio RR, Cox MS Jr, Trese MT, et al. Removal of epimacular membranes. *Ophthalmology* 1985;92:1075–1083.
18. Sandali O, El Sanharawi M, Basli E, et al. Epiretinal membrane recurrence: incidence, characteristics, evolution, and preventive and risk factors. *Retina* 2013;33:2032–2038.
19. Shimada H, Nakashizuka H, Hattori T, et al. Double staining with brilliant blue G and double peeling for epiretinal membranes. *Ophthalmology* 2009;116:1370–1376.
20. Sivalingam A, Eagle RC Jr, Duker JS, et al. Visual prognosis correlated with the presence of internal-limiting membrane in histopathologic specimens obtained from epiretinal membrane surgery. *Ophthalmology* 1990;97:1549–1552.
21. Balducci N, Morara M, Veronese C, et al. Retinal nerve fiber layer thickness modification after internal limiting membrane peeling. *Retina* 2014;34:655–663.
22. Patelli F, Radice P, Zumbo G, et al. 25-gauge macular surgery: results and complications. *Retina* 2007;27:750–754.
23. Fine HF, Iranmanesh R, Iturralde D, Spaide RF. Outcomes of 77 consecutive cases of 23-gauge transconjunctival vitrectomy surgery for posterior segment disease. *Ophthalmology* 2007;114:1197–1200.
24. Rizzo S, Belting C, Cresti F, Genovesi-Ebert F. Sutureless 25-gauge vitrectomy for idiopathic macular hole repair. *Graefes Arch Clin Exp Ophthalmol* 2007;245:1437–1440.
25. Tarantola RM, Tsui JY, Graff JM, et al. Intraoperative sclerotomy-related retinal breaks during 23-gauge pars plana vitrectomy. *Retina* 2013;33:136–142.
26. Ehrlich R, Goh YW, Ahmad N, Polkinghorne P. Retinal breaks in small-gauge pars plana vitrectomy. *Am J Ophthalmol* 2012;153:868–872.
27. Hikichi T, Kosaka S, Takami K, et al. Incidence of retinal breaks in eyes undergoing 23-gauge or 20-gauge vitrectomy with induction of posterior vitreous detachment. *Retina* 2012;32:1100–1105.
28. Nakano T, Uemura A, Sakamoto T. Incidence of iatrogenic peripheral retinal breaks in 23-gauge vitrectomy for macular diseases. *Retina* 2011;31:1997–2001.
29. Rizzo S, Genovesi-Ebert F, Murri S, et al. 25-gauge, sutureless vitrectomy and standard 20-gauge pars plana vitrectomy in idiopathic epiretinal membrane surgery: a comparative pilot study. *Graefes Arch Clin Exp Ophthalmol* 2006;244:472–479.
30. Gupta OP, Ho AC, Kaiser PK, et al. Short-term outcomes of 23-gauge pars plana vitrectomy. *Am J Ophthalmol* 2008;146:193–197.
31. Kusahara S, Ooto S, Kimura D, et al. Outcomes of 23- and 25-gauge transconjunctival sutureless vitrectomies for idiopathic macular holes. *Br J Ophthalmol* 2008;92:1261–1264.
32. Scartozzi R, Bessa AS, Gupta OP, Regillo CD. Intraoperative sclerotomy-related retinal breaks for macular surgery, 20- vs 25-gauge vitrectomy systems. *Am J Ophthalmol* 2007;143:155–156.