

Proportional Reflux Hydrodissection

The main goal of vitreoretinal surgery in the management of traction retinal detachments is the separation of pathologic fibrovascular tissue from normal retinal tissue. Historically, this has been accomplished by various specialized instruments, such as horizontal scissors, vertical scissors, membrane peeler cutters, forceps, etc. Using these instruments, surgical techniques such as bimanual dissection, membrane segmentation and en bloc dissection have been performed. The possibility of using a liquid substance to create the separation, instead of a hard metallic instrument, has obvious potential safety advantages. For this reason, the surgical technique of viscodissection was introduced several years ago.^{1,2} However, during this time, microincisional vitrectomy surgery had not been widely accepted and 20-gauge vitrectomy surgery was still the surgical gauge of choice. Although viscodissection is intellectually appealing, the amount of tissue separation that was required due to the size of the 20-gauge instruments was problematic. A typical 20-gauge cutter has the port located 0.43 mm behind the tip of the cutter. The amount of tissue separation needed was problematic. Often, simply, the attempt to perform viscodissection and introduce the larger cutter into the desired plane caused iatrogenic retinal tears.

Recent advances in microincisional vitrectomy surgery have been significant. As compared with the 20-gauge vitrectomy instrumentation, the new 25+ gauge vitrectomy probe is not only smaller but the port is located 46% closer to the tip. Moreover, the port is also 59% larger than the original 25-gauge vitreous cutter. Therefore, theoretically, the amount of tissue separation required should be considerably less. The idea of fluid-based tissue separation was revisited.

For a number of years, vitrectomy machines have provided the surgeon with the ability to reflux tissue from the port of the vitreous cutter if accidental

incarceration of normal retinal tissue should occur. The click of the foot pedal to one side would allow for a pulse of fluid to be ejected from the port, thereby disengaging the accidentally incarcerated tissue. The Constellation Vision System (Alcon Laboratories, Fort Worth, TX) has this pulse reflex mode but, in addition, it also has a proportional reflux mode. The proportional reflux mode allows for fluid to be ejected from the port in a gradual and controlled manner with foot pedal control, thus the term proportional reflux.

Given the advantage of the smaller size of the 25+ vitreous cutter and the ability to inject fluid in between normal retina and fibrovascular tissue in a proportional and controlled fashion, the author has explored the technique of proportional reflux hydrodissection. This idea was first imbibed to the author by David Buboltz in Alcon Laboratories.

Concurrent development of microincisional vitrectomy surgery with not only a smaller gauge but also with the port being closer to the tip and the development of proportional reflux has allowed for a new surgical technique that the author has named “proportional reflux hydrodissection.” In this technique, the port of the cutter is placed between the fibrovascular tissue and the normal retinal tissue. Thereafter, with the foot pedal, the surgeon has complete control over fluid extrusion in a proportional fashion to create a separation between the fibrous tissue and the normal retina. Because of the optimal location of the port to the tip, only a small separation is required. Once this separation is created, the cutter may be used to dissect the fibrovascular tissue away from the normal retinal

From the Retinal Consultants of Arizona, Phoenix, Arizona; Department of Ophthalmology, Doheny Eye Institute, Keck School of Medicine, University of Southern California, Los Angeles, California; Spectra Eye Institute, Sun City Arizona.

Supported in part by Alcon Laboratories. Pravin U. Dugel, MD, is a consultant to Alcon Surgical.

The authors have no financial interest in any of the procedures or products mentioned in this article.

Reprint requests: Pravin U. Dugel, MD, Retinal Consultants of Arizona, Ltd., 1101 East Missouri Avenue, Phoenix, AZ 85014; e-mail: pdugel@gmail.com

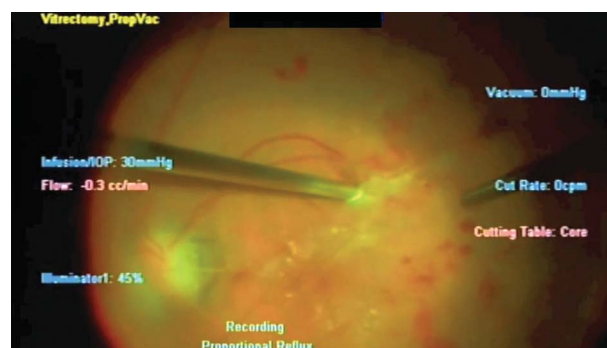

Fig. 1. Proportion reflux hydrodissection in complex combined rhegmatogenous and tractional retinal detachments using the 25+ gauge vitrectomy system.

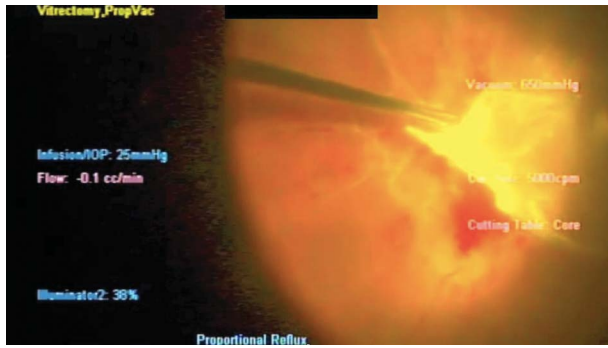


Fig. 2. Proportion reflux hydrodissection in complex combined rhegmatogenous and tractional retinal detachments using the 25+ gauge vitrectomy system.

tissue (Figures 1–3). The author has used this technique in more than 100 patients with a complicated traction retinal detachment. This technique offers numerous advantages. First, in complex cases with a combined traction rhegmatogenous retinal detachment, it allows for simultaneous separation of the fibrovascular tissue while allowing for normal retinal tissue to be pushed away from the port of the cutter. Second, no additional instrumentation or equipment is required. Third, this is an efficient surgical technique only requiring a click of the foot pedal without removing the vitreous cutter from the eye.

This technique has allowed the author to perform numerous complicated cases with the cutter alone, without the introduction of any other instrumentation. There is efficiency, safety, and economic advantage to this surgical technique. In reviewing cases of more than 100 patients with a complicated traction retinal detachment, the author has successfully used this technique alone in approximately 75% of patients. It must be said that there are very complex cases that will still require additional instrumentation, such as horizontal scissors, and techniques, such as the bimanual dissection technique. However, it is both time- and cost-efficient to try proportional reflux hydrodissection first and, if insufficient, then convert to traditional dissection techniques.

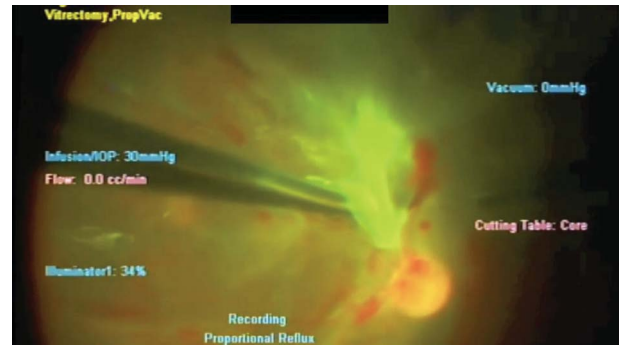


Fig. 3. Proportion reflux hydrodissection in complex combined rhegmatogenous and tractional retinal detachments using the 25+ gauge vitrectomy system.

In conclusion, the advent of microincisional vitrectomy surgery and the advent of a new modality known as proportional reflux has allowed the development of a new surgical technique known as proportional reflux hydrodissection. This technique is found to be useful in patients with a complicated traction retinal detachment or a combined complicated traction rhegmatogenous retinal detachment. Advantages of this technique are that it is simple, cost-effective, and does not preclude the use of traditional techniques if needed. As I learn to use this technique, it has become more prevalent in patients with such complex detachments.

Key words: hydrodissection, proportional reflux, microincisional vitrectomy surgery, surgical technique, vitrectomy surgery, traction retinal detachment.

PRAVIN U. DUGEL, MD

References

1. Crafoord S, Stenkula S. Healon GV in posterior segment surgery. *Acta Ophthalmol (Copenh)* 1993;71:560–561.
2. Stenkula S, Ivert L, Berglin L, Crafoord S. Healon Yellow as a surgical tool in maneuvering intraocular tissues. *Ophthalmic Surg* 1992;23:708–710.