

Cotton-Tip Applicator Lid Retraction Technique for Controlled Intravitreal Injection

Intravitreal injection of anti-vascular endothelial growth factor agents for retinal, vascular, and macular disease has become one of the most commonly performed medical procedures worldwide. Safety, cost, and patient comfort issues are thus of huge importance. The majority of retina specialists uses a lid speculum,¹ although it may be associated with significant patient discomfort as it stretches the medial and lateral canthi.² Only upper lid retraction with a metal hemispeculum (Desmarres) has been recently tried.³ A bimanual “two-person” injection method has been presented as well.⁴ An alternative technique is presented here.

Surgical Technique

The patient is placed in an upright seated position with only the head slightly extended in a regular examination chair. Topical anesthesia is provided with a drop of tetracaine 0.5%, and then the skin, lids, and lashes are prepped with povidone-iodine 10% solution. Several drops of povidone-iodine are then placed over the eye and into the conjunctival cul-de-sac. The eye is immediately irrigated with several drops each of tetracaine 0.5% and a Fluoroquinolone antibiotic, and the eyelids are wiped dry with a sterile 4 × 4 wipe. A cotton-tip applicator swab, the tip of which has been well soaked with tetracaine 0.5% and an antibiotic drop, is then placed directly against the eye and under the temporal aspect of the upper eyelid, and the patient is instructed to “close the eye and relax for a minute” (Figure 1). The injecting physician typically stays in the room during this time period. After 1 minute to 2 minutes, the patient is instructed to look down (and into adduction) and to either the right or the left side based on laterality. Then they are instructed to open the eye, and the just aforementioned directional instruction is repeated. This exposes the superior-temporal bulbar conjunctiva. The lid is then maintained in elevation by the applicator stick, and the eye is somewhat stabilized in infra-adduction by its contact with the cotton-tip

(Figure 2). Some counter-pressure or active control of eversions can be taken if necessary with the applicator, although this is seldom necessary. An injection is then given with either a 30-gauge or 31-gauge needle approximately 3.5 mm to 3.75 mm from the limbus (Figure 3). After the injection is administered and the needle withdrawn, the cotton tip is immediately moved over the injection site (Figure 4) to minimize efflux of material and then removed as the lids are allowed to close.

The author has safely performed ~2,000 consecutive intravitreal injections with this technique. Five patients have required the use of a sterile lid speculum upon repeated injection due to excessive squeezing. Most of the injections (>90%) were with bevacizumab (Avastin). There has been only one noted corneal abrasion and no incidence of lens damage, retinal breaks, or endophthalmitis.⁵ One very elderly aphakic patient

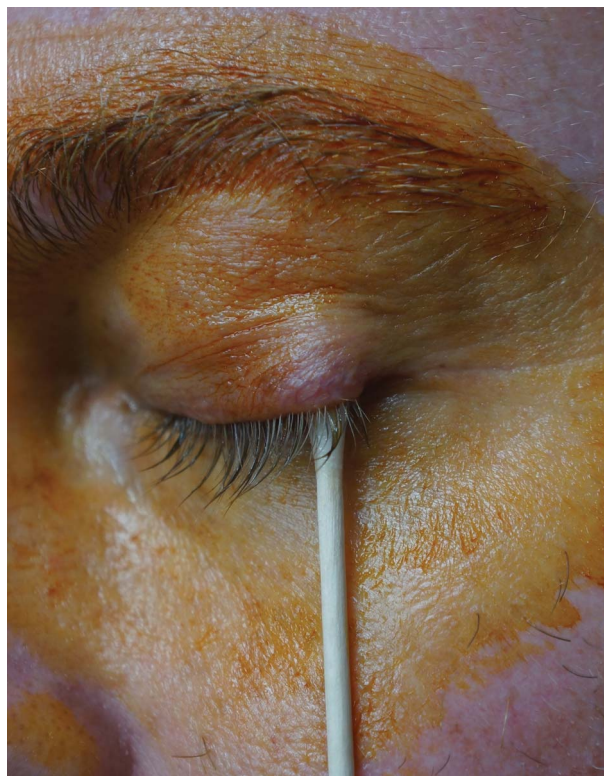

Fig. 1. The cotton-tip applicator is applied under the outer third of the eyelid.

From the Department of Ophthalmology, SUNY Downstate College of Medicine, Brooklyn, New York.

Reprint requests: Eric M. Shrier, DO, SUNY-Downstate UHB, Department of Ophthalmology, Box # 58, 450 Clarkson Avenue, Brooklyn, NY 110203; e-mail: eshrier@yahoo.com

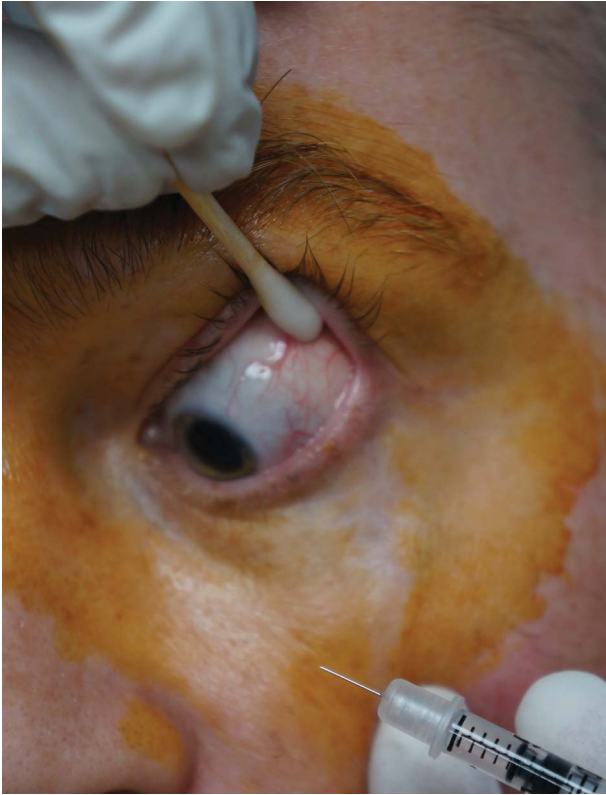

Fig. 2. The cotton-tip applicator is used to maintain the upper eyelid in the open position because the patient looks down in adduction. The cotton-tip portion of the applicator can be used to apply pressure to the globe to maintain infra-adduction.

developed an inferior retinal detachment several weeks after a repeated injection of Avastin for choroidal neovascularization.

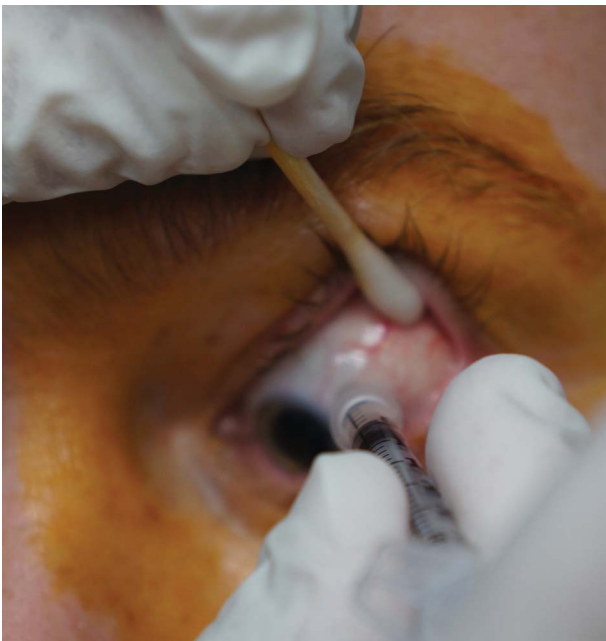

Fig. 3. An injection is administered and needle withdrawn.

Discussion

This truly bimanual independent surgical technique allows isolation of the injection site from the lids and lashes as a potential source of infection. It is innovative in that it simultaneously permits both retraction of the upper eyelid and some mechanical control of the eye itself. The cotton-tip applicator as a surgical tool is very unique in that it is ubiquitous and cost-effective. It is potentially maneuverable to a great advantage and is not heavy or cumbersome as is a metal (or disposable) eyelid speculum or motility-neutral as the wire-lid or the Desmarres retractor. It may also have an additional benefit of supplementing topical anesthesia as 2 minutes of pressure contact with anesthetic directly upon the injection site is achieved. The cotton-tip portion of the applicator is then readily available to fully tamponade the injection site so as to disallow (or to permit) egress of the drug. Superior intravitreal injection is the author's preference because it seldom causes significant subconjunctival hemorrhage and would theoretically result in more easily treatable superior retinal break and/or retinal detachment if iatrogenic pathology were ever encountered. The technique has been very safe, well-tolerated, and seems to be cost-effective. The technique could presumably be modified for inferior injection if desired.

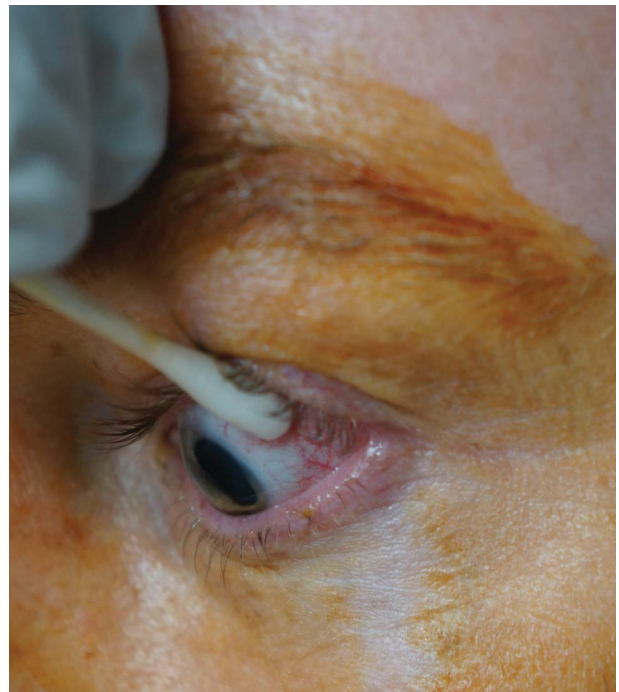


Fig. 4. The cotton tip is placed or rolled over the injection site with the side opposite that which contacted the lid.

Key words: intravitreal injection, lid speculum, eyelid speculum, topical anesthesia, cotton-tip applicator, cost-effective procedure, IOP and intravitreal injection.

ERIC M. SHRIER, DO

References

1. Green-Simms AE, Ekdawi NS, Bakri SJ. Survey of intravitreal injection techniques among retina specialists in the United States. *Am J Ophthalmol* 2011;151:329–332.
2. Tailor R, Beasley R, Yang Y, Narendran N. Evaluation of patients' experiences at different stages of the intravitreal injection procedure—what can be improved? *Clin Ophthalmol* 2011;5:1499–1502.
3. Mason RH. Use of a Desmarres retractor for upper lid and lash isolation during intravitreal injection. *Retina* 2013;33:2175–2176.
4. Fineman MS, Hsu J, Spirm MJ, Kaiser RS. Bimanual assisted eyelid retraction technique for intravitreal injections. *Retina* 2013;33:1968–1970.
5. Dastgir G, Danias J, Shrier E. Impact of intravitreal bevacizumab on intraocular pressure. *IOVS ARVO e-abstract* 2970/A415, May 2012.