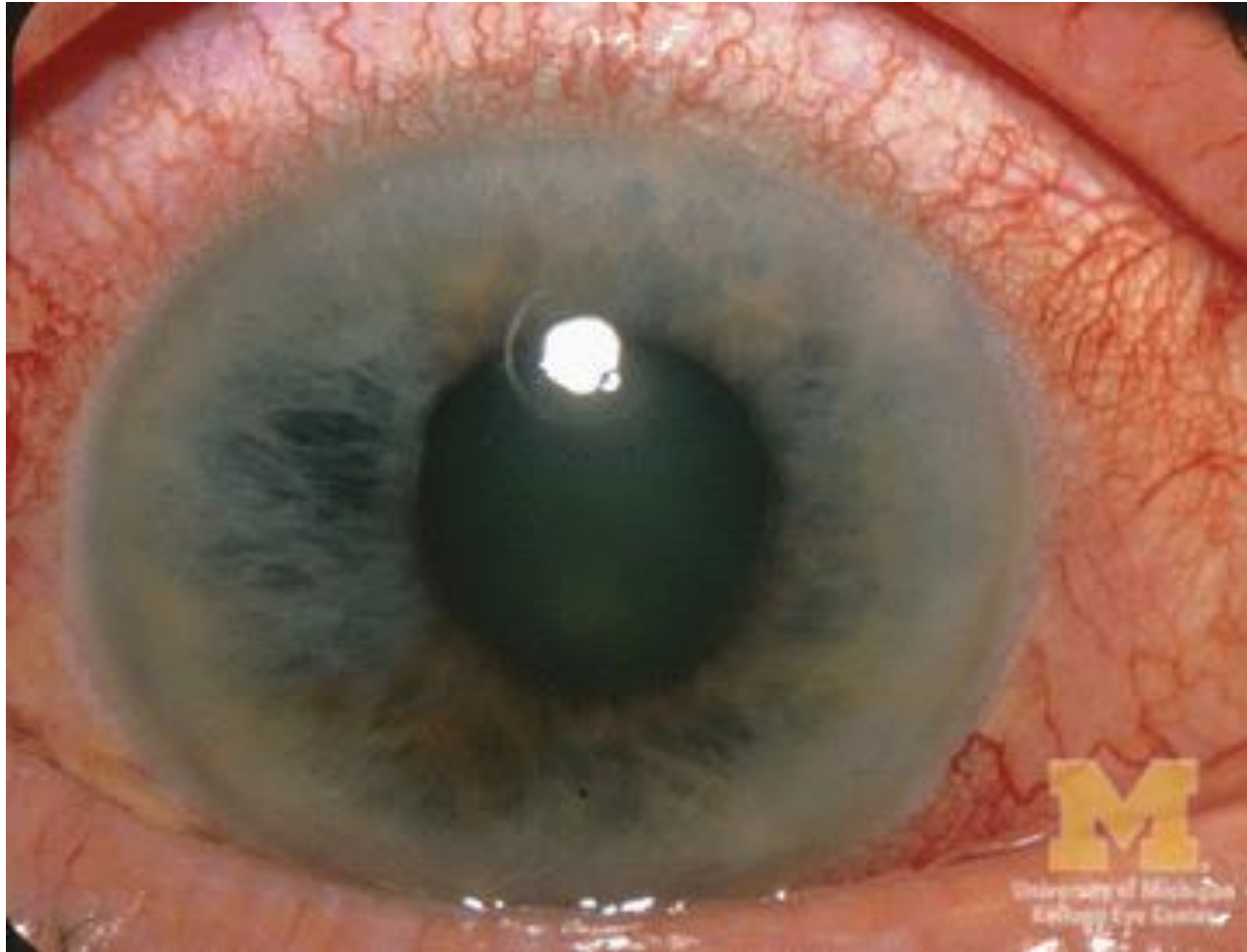

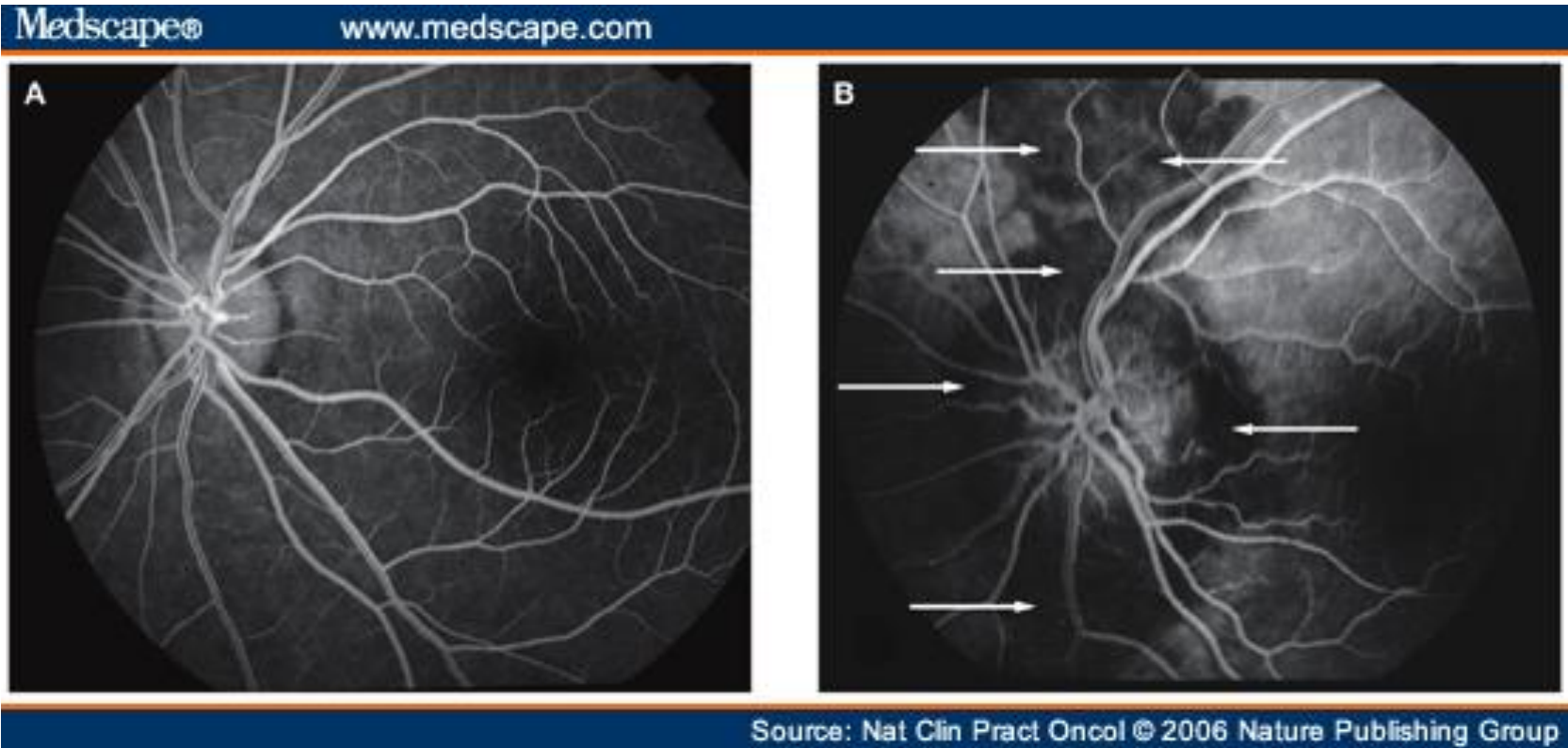
# Ophtho 101

## Pictures for Group Discussion

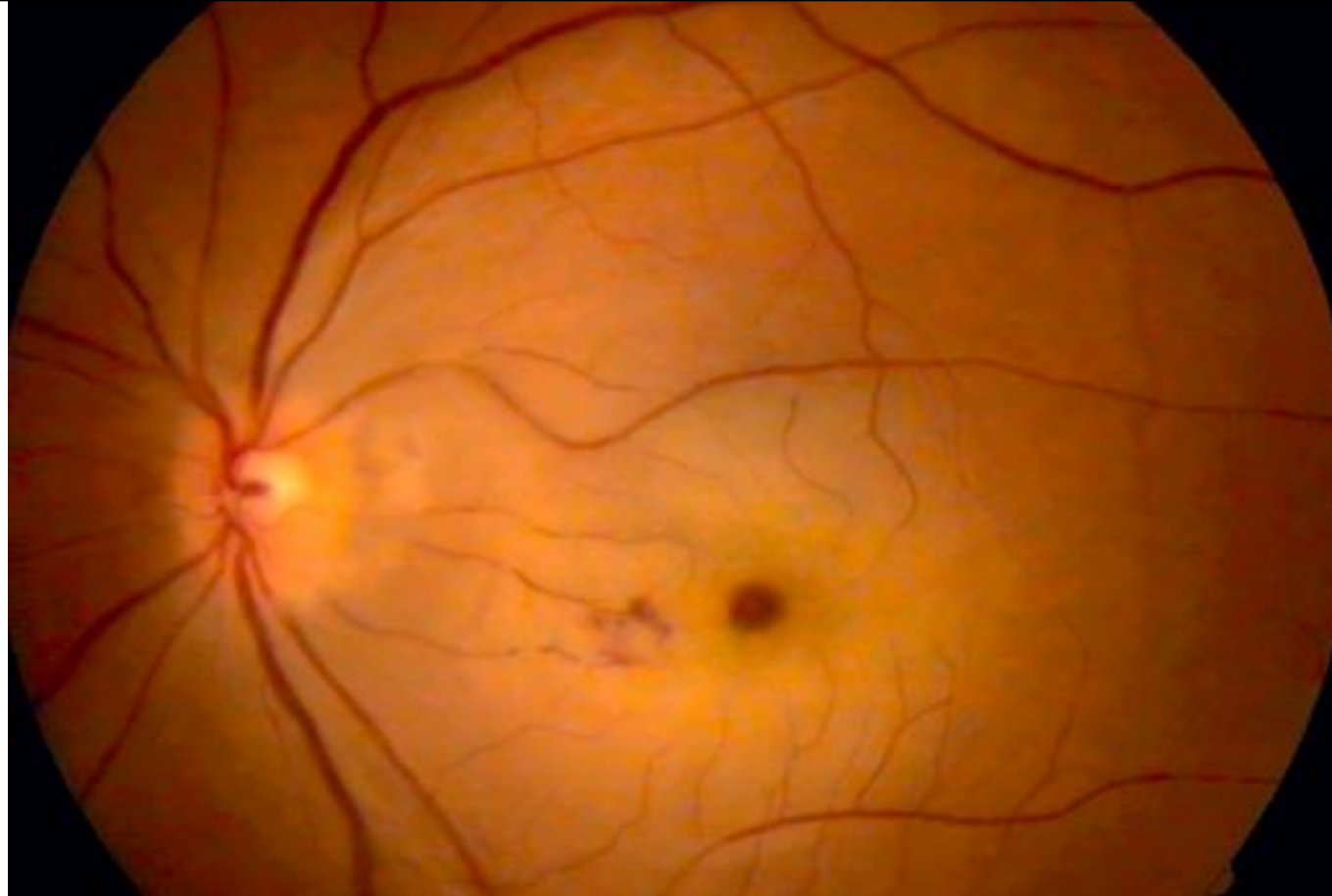
University of Louisville Department of Ophthalmology and Visual Sciences



- What are the top 3 in the differential for explaining this painful red eye?
- Describe the eye findings found in this photo
- How will this likely be treated by the Ophthalmologist?

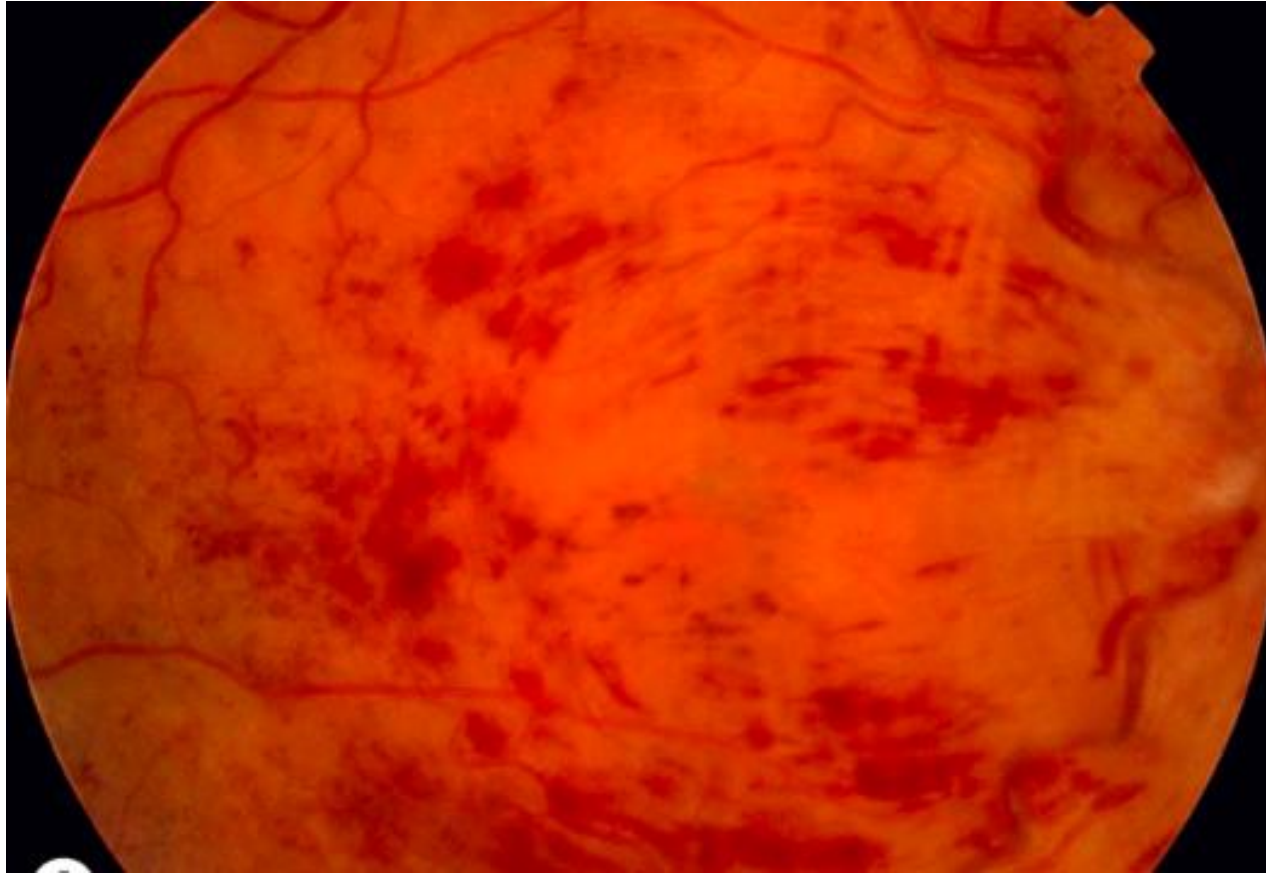


What systemic symptoms are associated with this vascular abnormality demonstrated in an elderly patient? How should this disease be managed in the acute setting?



1) Describe this fundus photo.

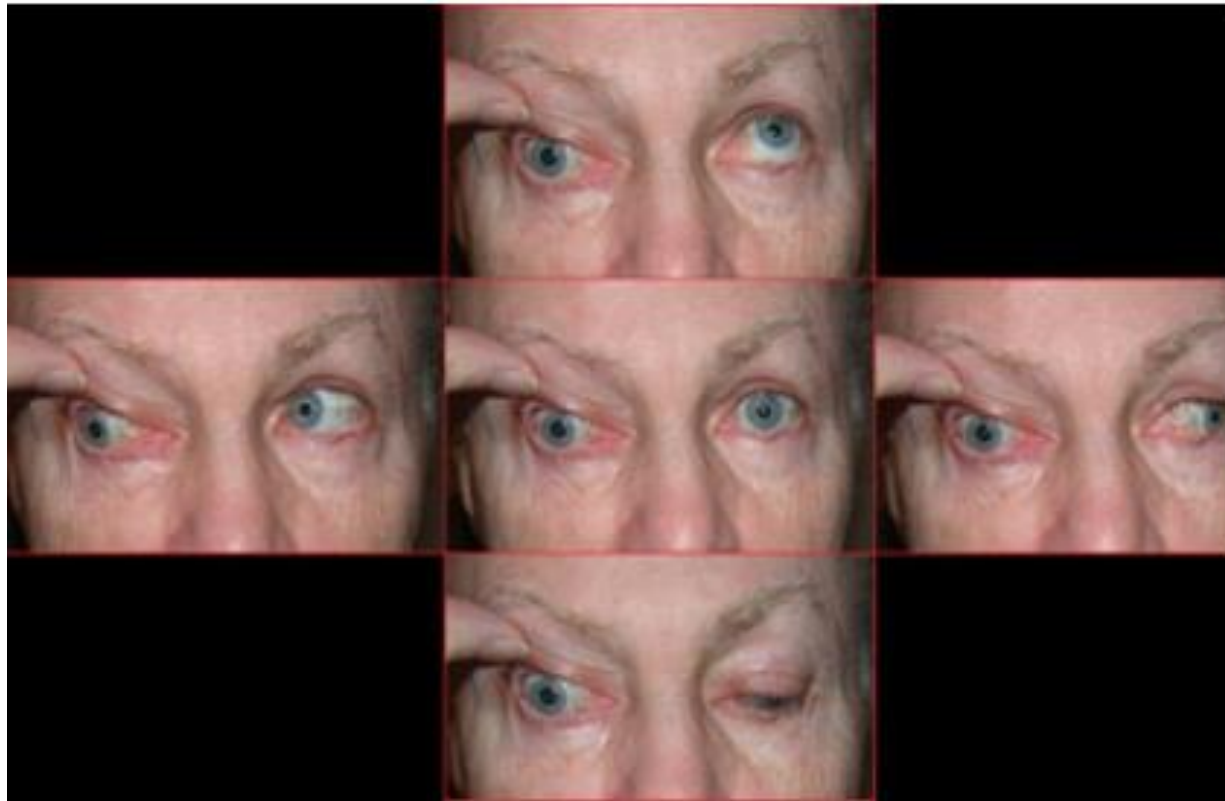2) What workup is indicated when this condition is diagnosed?



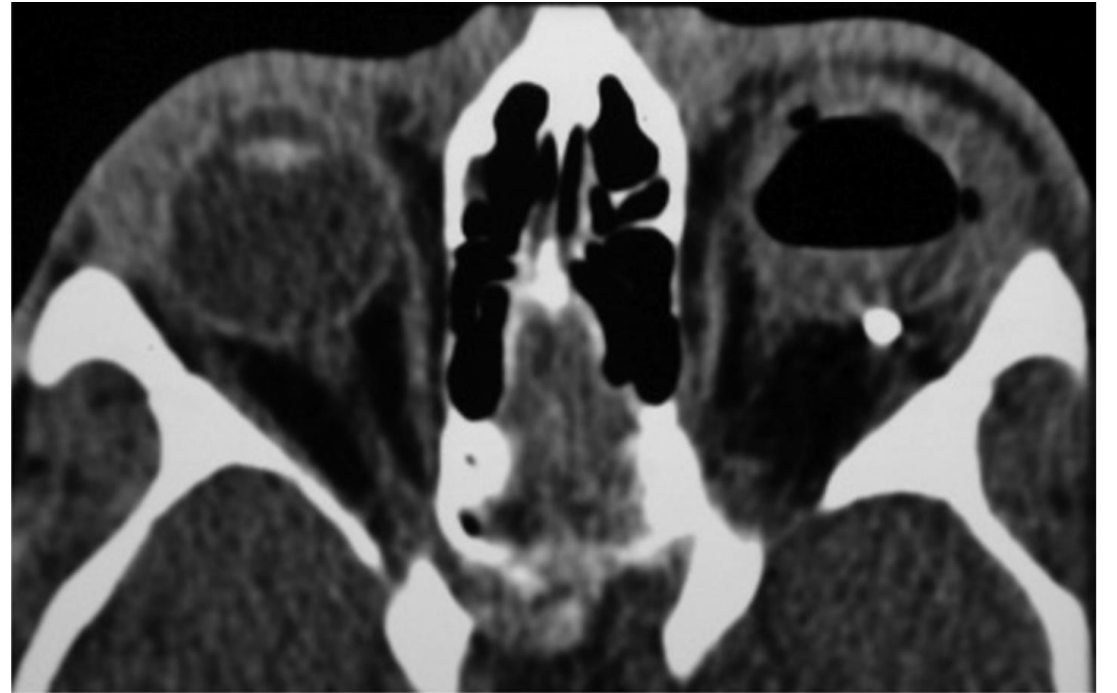
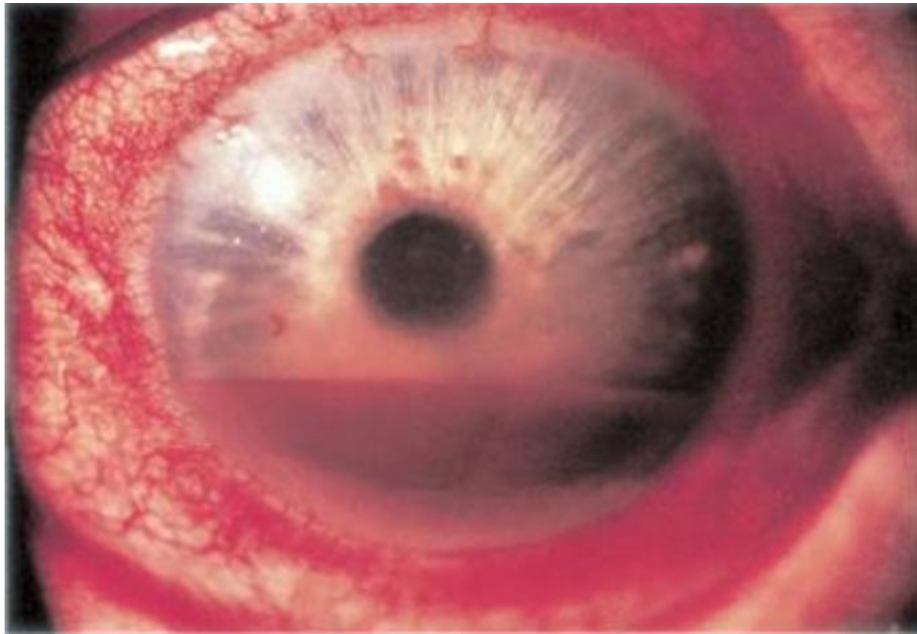Name some of the risk factors associated with this condition



65 year old smoker reports a painless, ten minute disturbance of his visual field. What is the differential? Workup indicated?

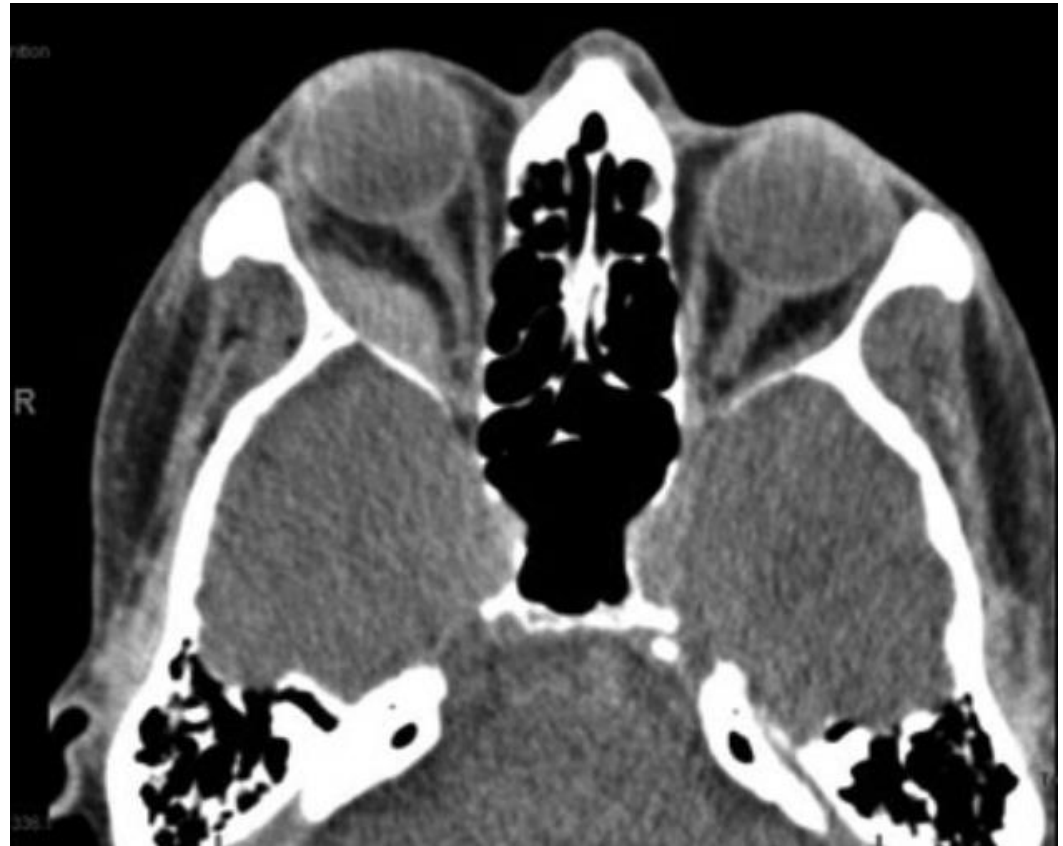
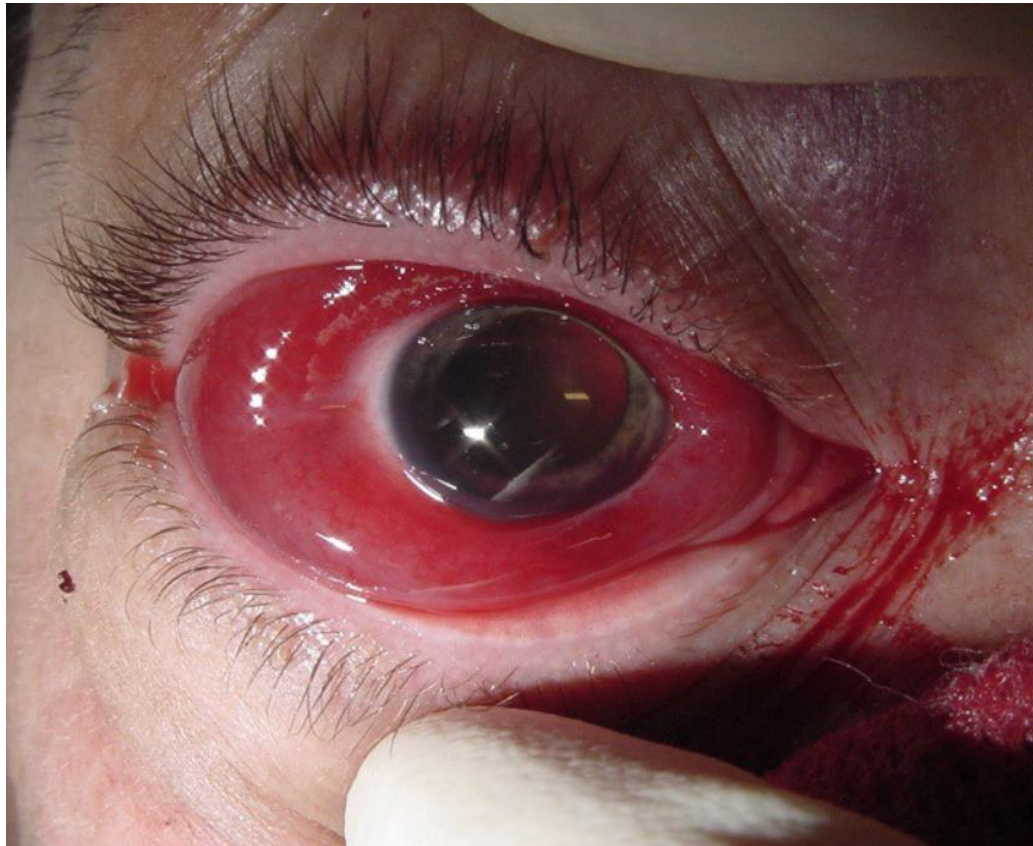
- Describe the pathologic eye findings in this photo
- What condition might explain these findings?
- What workup is indicated?

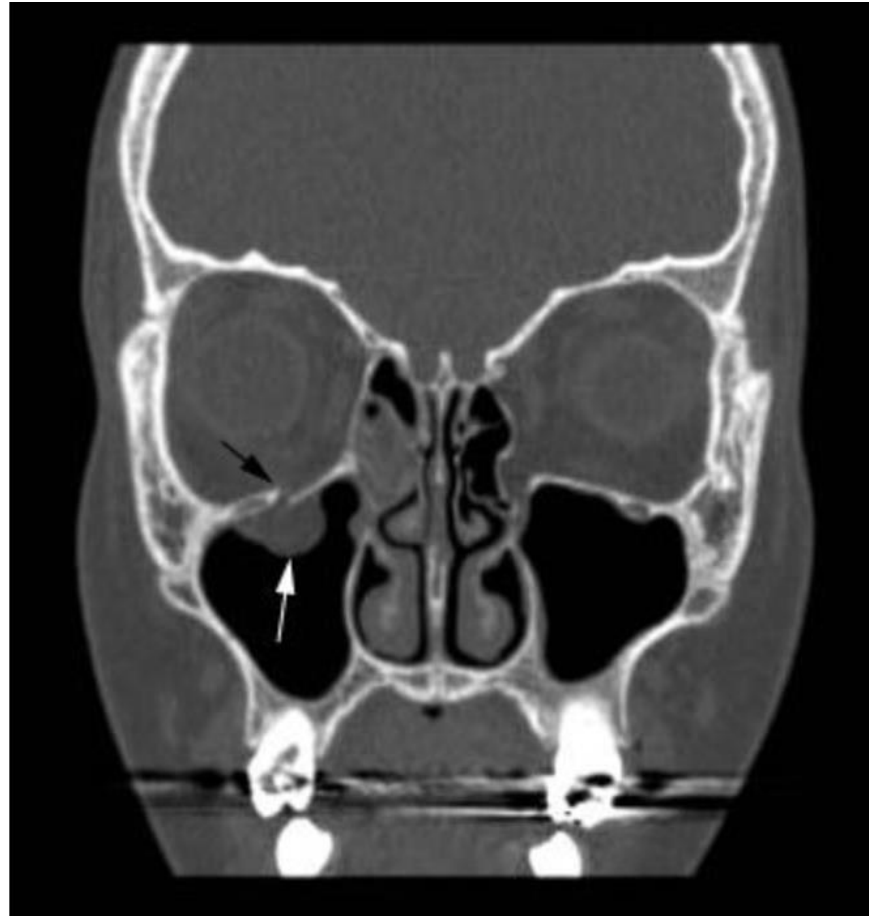


- Describe the eye findings seen above using appropriate terminology to describe the conjunctiva, cornea, anterior chamber. What type of scan and cut is seen in the radiologic figure?
- What is the workup indicated if this is seen?





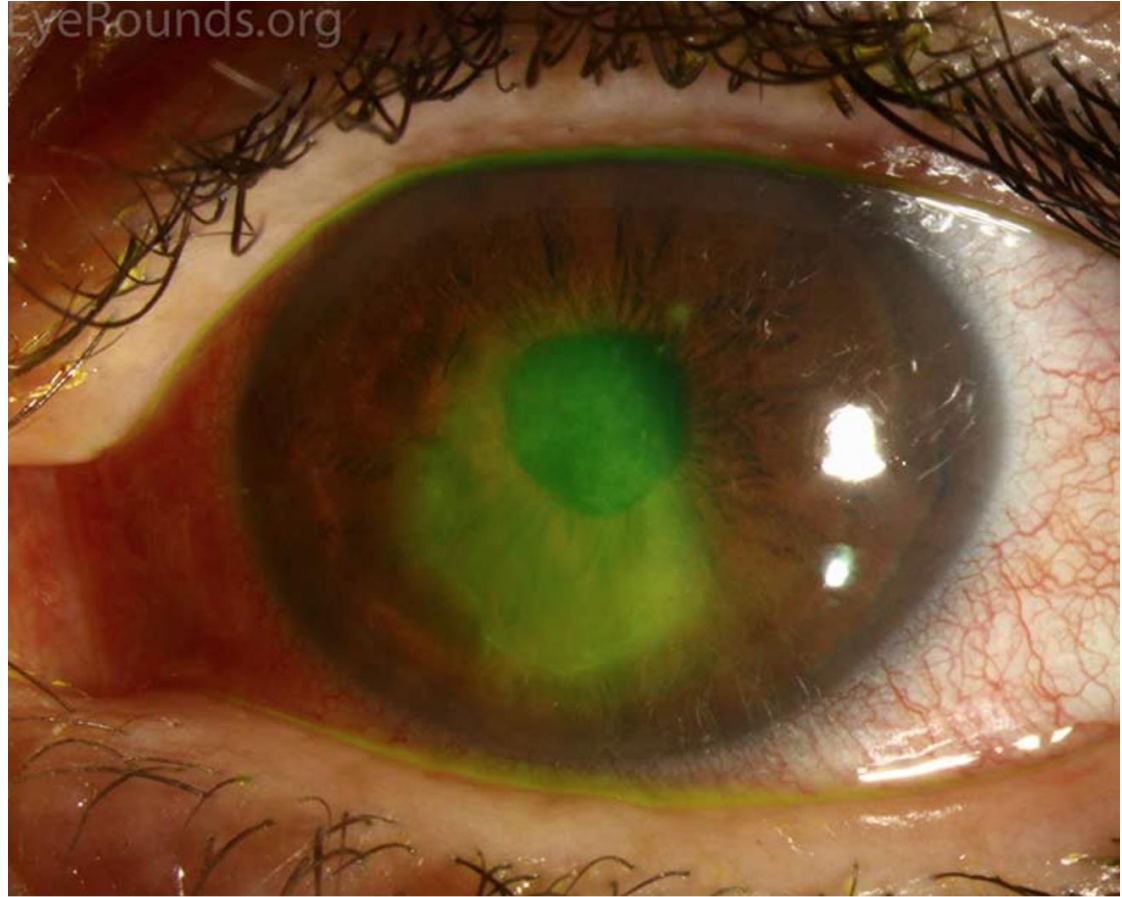- What is going on in these two photos?
- What intervention is indicated?



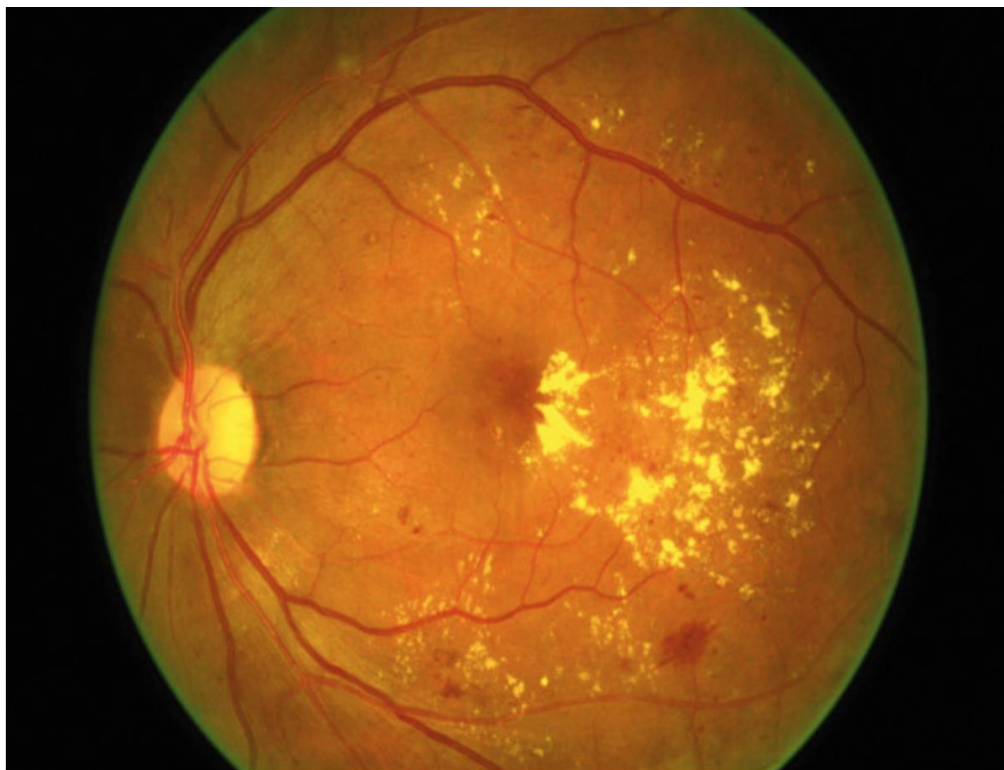
- What type of scan is this? What radiologic findings are present?
- How is this condition typically managed?



- In what situation would this be helpful in Ophthalmology?
- What are the steps surrounding its utilization?

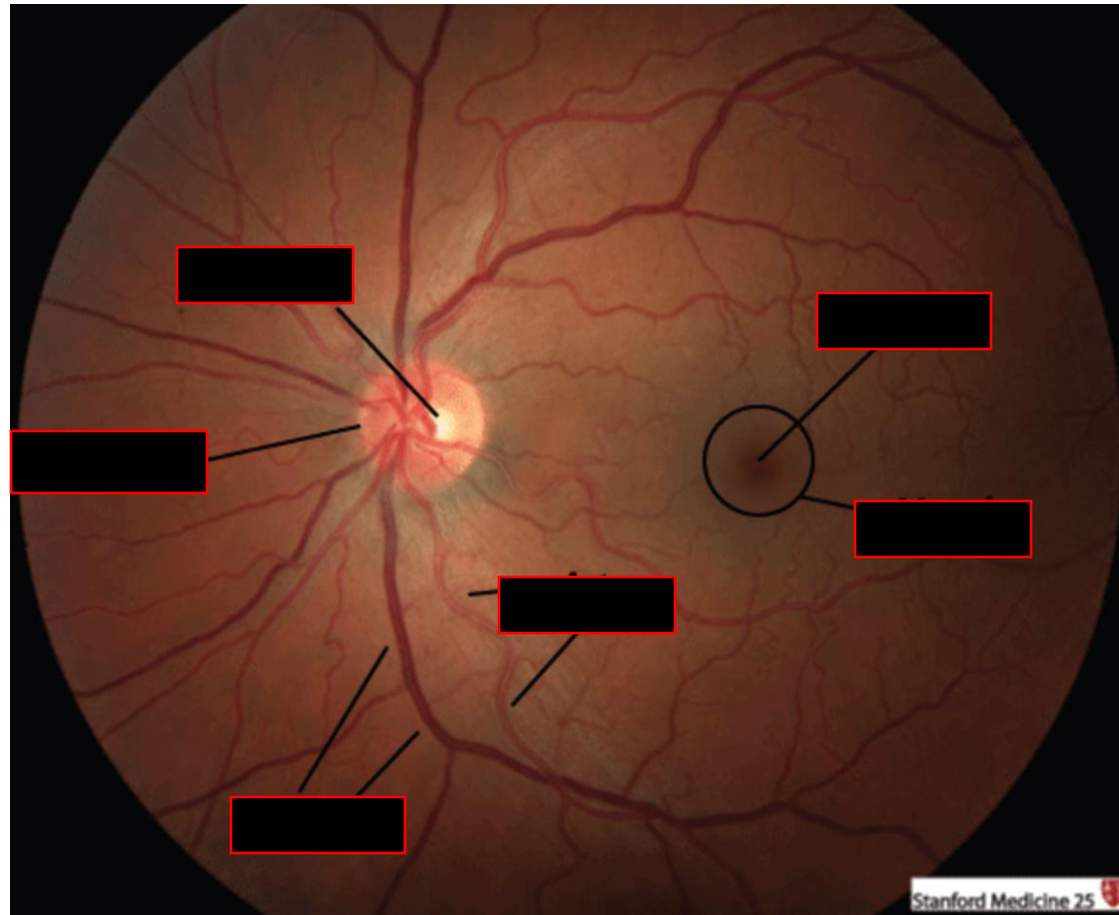


What is the dye utilized in this photo? What is it detecting?  
How is this condition typically managed?

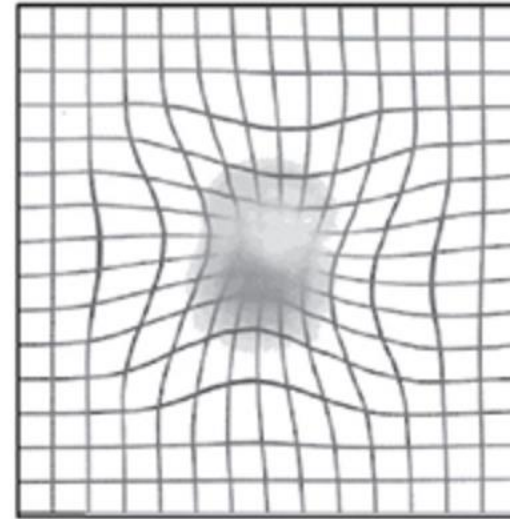



What is in the differential for this clinical fundus photo?  
What are the treatment options?

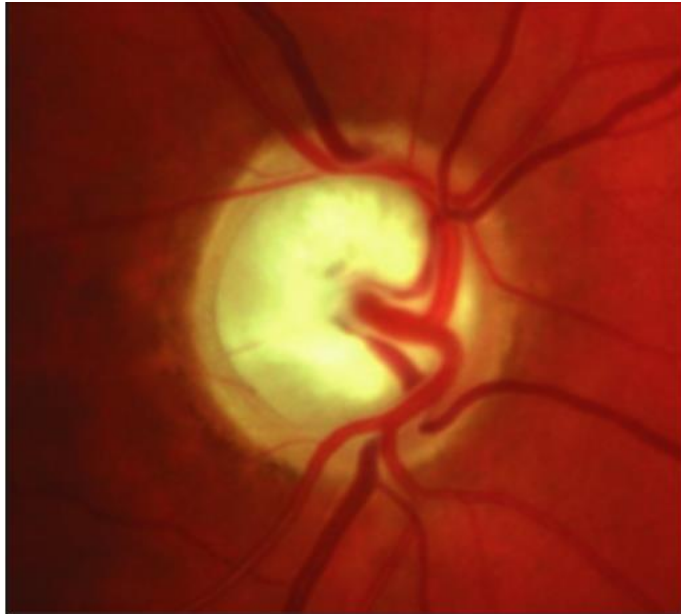
# Basic Eye Exam




Label the basic components of this clinical fundus photo



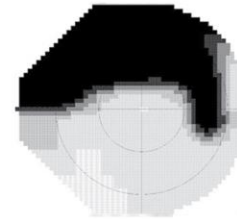
What is this figure used for in Ophthalmology?  
What are the risk factors associated with this condition?  
What clinical findings are present in the fundus?



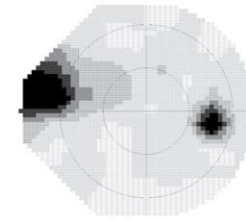
A Normal visual field



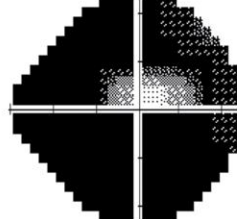
B Superior arcuate defect



C Superior nasal step defect

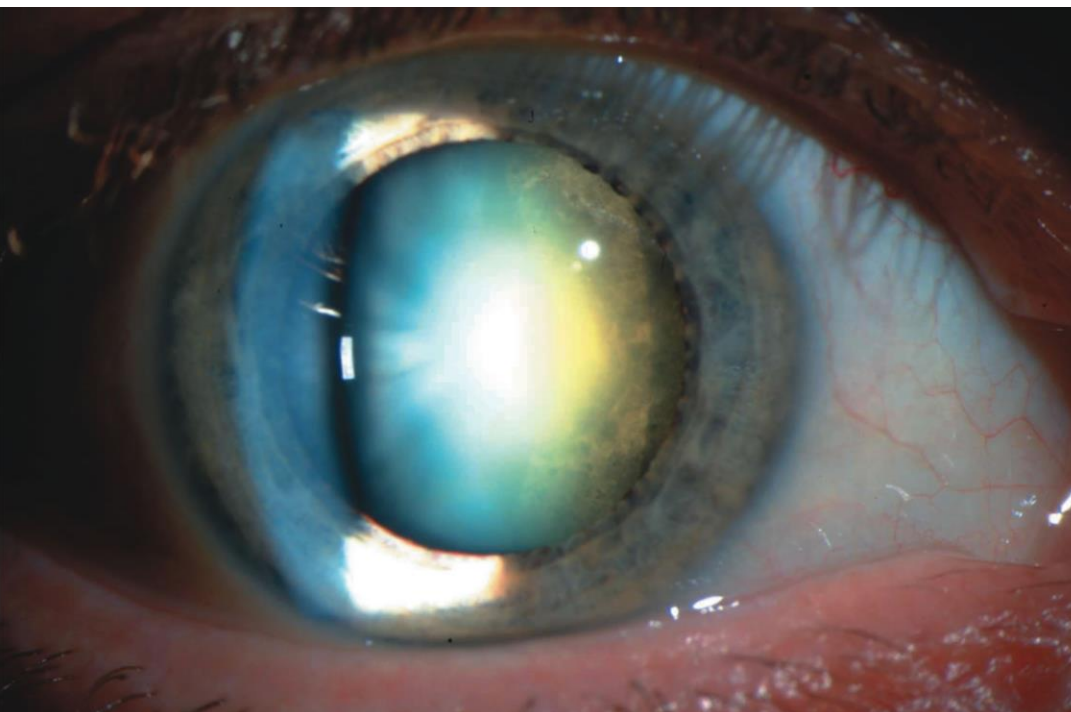


D visual field defects

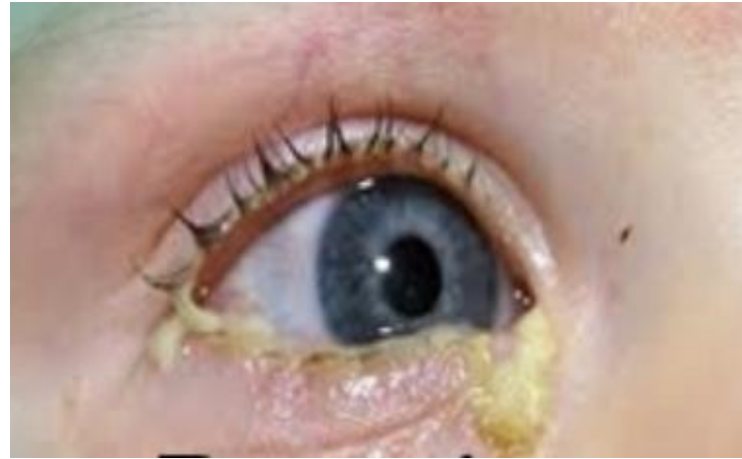
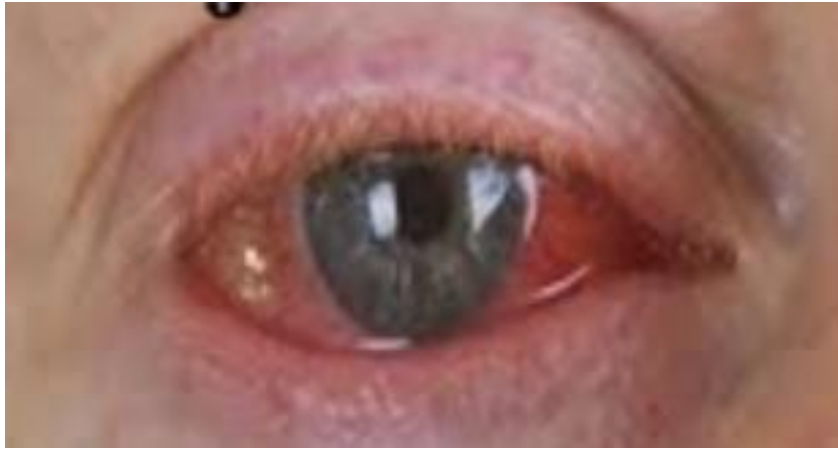
- What classic finding of the Optic Nerve is seen here? What condition is it associated with?
- What is the significance of the included visual fields?
- What are some of the common treatment options for this condition?

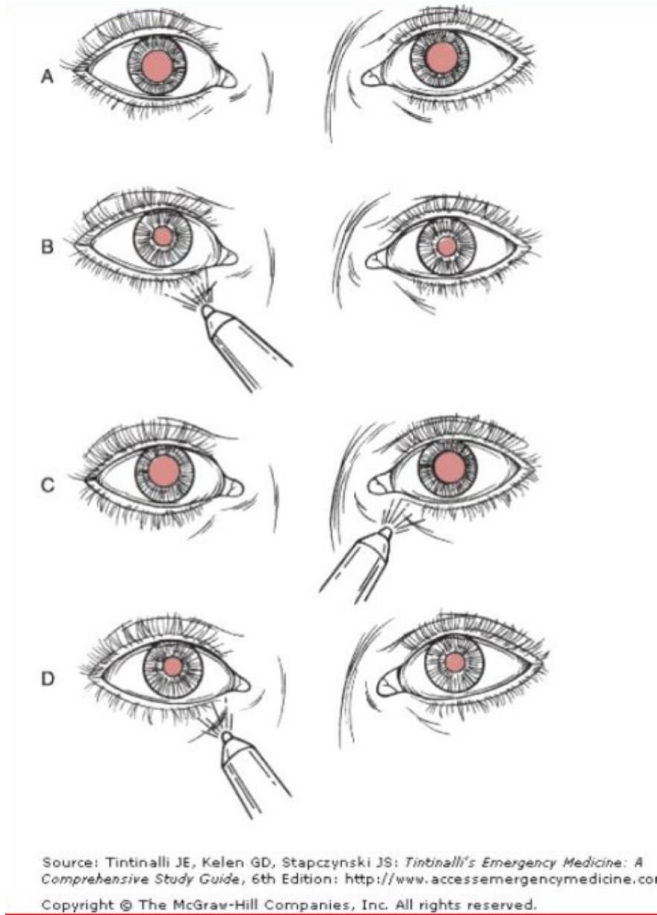




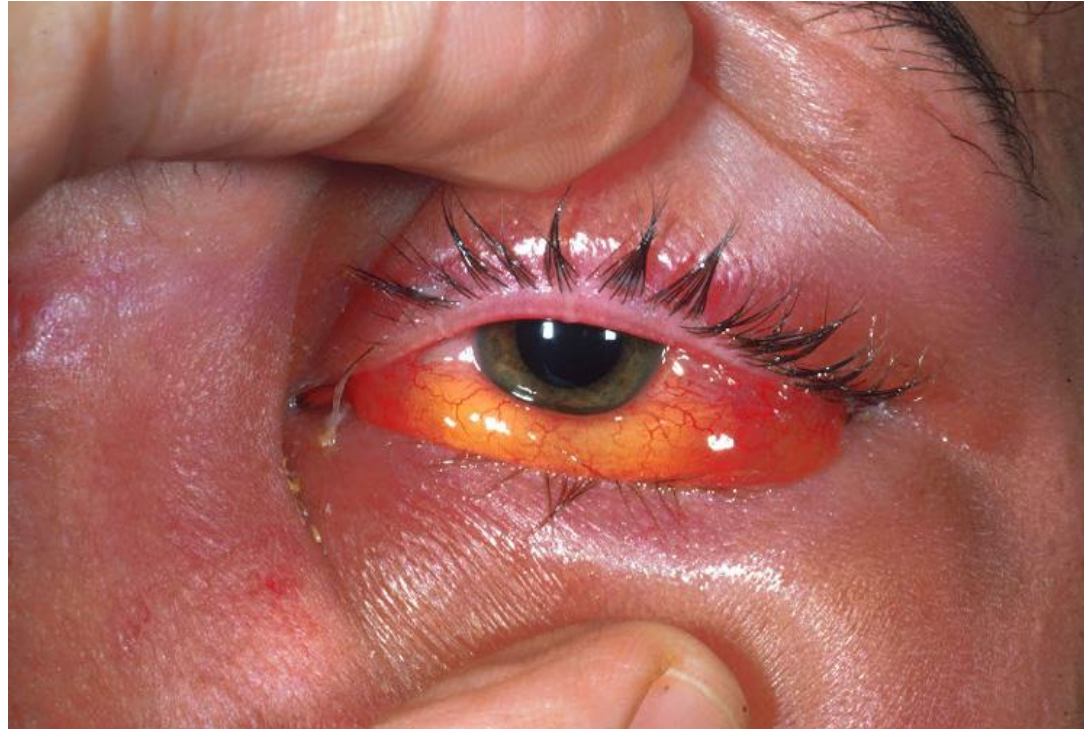- What type of symptoms might this patient describe when visiting the ophthalmologist?
- How common is this condition?
- Briefly describe the corrective measures



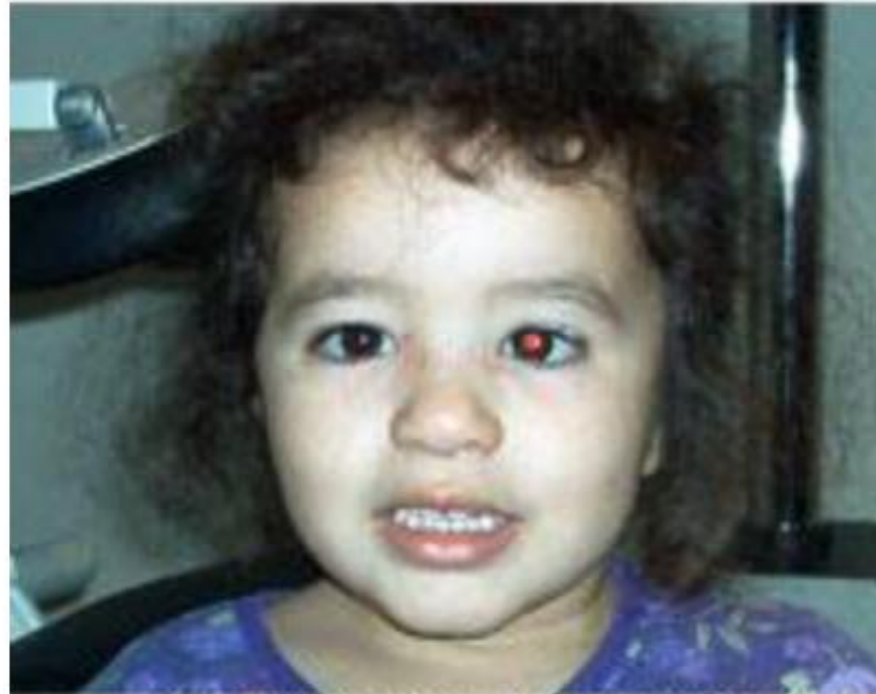Which photo is likely bacterial conjunctivitis? Viral?  
What are a few of the key distinctions between the two?



- 1) What is the name of the above test? Which eye is abnormal?
- 2) What are some of the common conditions associated with this finding?

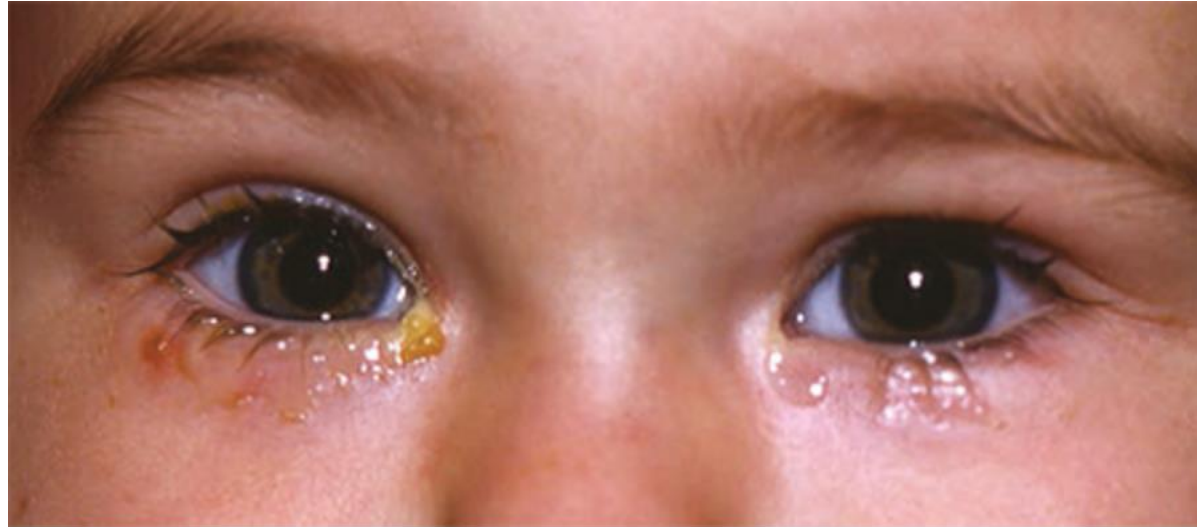

-This patient presents with a 2 day history of eye pain, swelling, and discharge. What are the most important clinical findings to look for when deciding how serious to manage his condition?

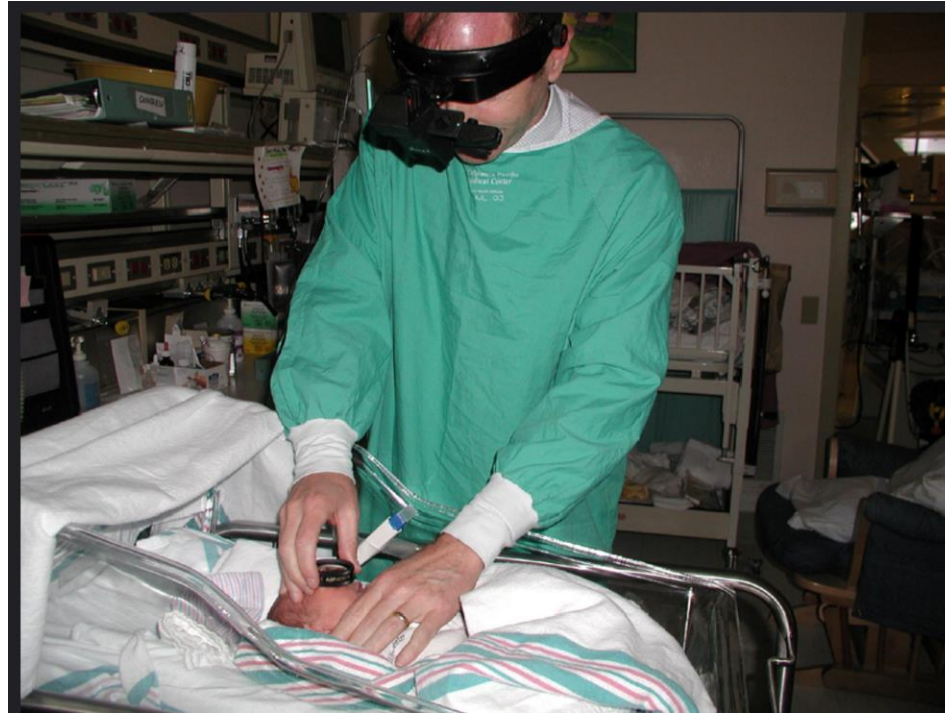

© 2014 American Academy of Ophthalmology

What is in the differential diagnosis for this photo?  
How is the red reflex test performed?  
Why is it imperative to intervene early for many of the pediatric conditions causing this?



What is the most likely explanation for this clinical photo?  
How is this condition typically managed?  
What other diseases are important to rule out?



Why might this Ophthalmologist be examining this baby in the NICU?  
What are the precise screening criteria?  
What are the available options for treatment?