

OUTCOMES OF REPEATED PARS PLANA VITRECTOMY FOR PERSISTENT MACULAR HOLES

ELAD MOISSEIEV, MD,* IDO D. FABIAN, MD,† JOSEPH MOISSEIEV, MD,‡ ADIEL BARAK, MD*‡

Purpose: To evaluate the efficacy of repeated pars plana vitrectomy with internal limiting membrane peeling and gas tamponade for persistent macular holes (MHs).

Methods: Twenty-nine eyes that underwent repeated pars plana vitrectomy and internal limiting membrane peeling for persistent MHs were included in this retrospective study. Data retrieved included demographic information, visual acuity before the first and second surgeries, MH diameter before and after both surgical procedures and throughout the follow-up, surgical details, time between surgeries, final visual acuity, and the occurrence of any complications.

Results: Reoperation achieved closure of the persistent MH in 68.9% of the eyes. Final visual acuity improved significantly when compared with that before the second surgery, and postoperative complications were minimal. Reoperation achieved significant improvement in visual acuity ($P < 0.001$), and 62% of patients gained >2 lines. The final visual acuity was significantly better in eyes with closed MH after the second surgery than that in eyes where it persisted (0.68 ± 0.37 vs. 1.17 ± 0.25 logarithm of the minimum angle of resolution, respectively, $P = 0.002$). Shorter interoperative time and smaller initial MH diameter were significantly correlated with better visual prognosis ($P = 0.029$ and 0.005 , respectively).

Conclusion: Repeated pars plana vitrectomy with internal limiting membrane peeling and gas tamponade is a safe and effective treatment option for persistent MHs. Earlier reoperation is recommended for greater visual recovery.

RETINA 33:1137–1143, 2013

For the past two decades, idiopathic macular holes (MHs) have been treated successfully by pars plana vitrectomy (PPV). Kelly and Wendel¹ pioneered this technique and achieved an anatomical closure rate of 73% and improvement in visual acuity of 2 lines or more in 55% of cases.² Since then, the surgical technique has been refined and currently consists of vitrectomy, induction of posterior vitreous detachment, internal limiting membrane (ILM) peeling, and intraocular gas tamponade, followed by facedown positioning of the patient. In recent years, peeling of the ILM has been shown by numerous studies to improve the rate of anatomical closure of MHs,^{3–7} and it has become an accepted part of the surgical technique for this indication.

Current studies report anatomical closure rates of 85% to 100% in MH surgery, with visual improvement in as much as 85% to 95% of patients.^{8–12} In the minority of cases, MHs persist despite surgery. Relatively, few studies have focused on persistent MHs, which are associated with poor visual prognosis. Most studies concerning treatment of persistent MHs included use of different surgical techniques than that used initially, such as using heavy silicone oil^{13–15} or inducing macular detachment.¹⁶ Only two studies evaluated retreatment of persistent MHs by repeated PPV with gas tamponade. However, in one of them,¹⁷ the ILM was peeled only in the second procedure and the second¹⁸ included both recurrent and persistent MHs. The purpose of this study was to evaluate the efficacy of repeated PPV with ILM peeling and gas tamponade for persistent MHs.

From the *Department of Ophthalmology, Tel Aviv Sourasky Medical Center, Tel Aviv, Israel; †Department of Ophthalmology, Sheba Medical Center, Tel Hashomer, Israel; and ‡Sackler Faculty of Medicine, Tel Aviv University, Tel Aviv, Israel.

None of the authors have any financial/conflicting interests to disclose.

Reprint requests: Elad Moisseiev, MD, Department of Ophthalmology, Tel Aviv Sourasky Medical Center, 6 Weizmann Street, Tel Aviv 64239, Israel; e-mail: elad_moi@netvision.net.il

Methods

The records of the ophthalmology departments in two large medical centers in Israel, the Tel-Aviv

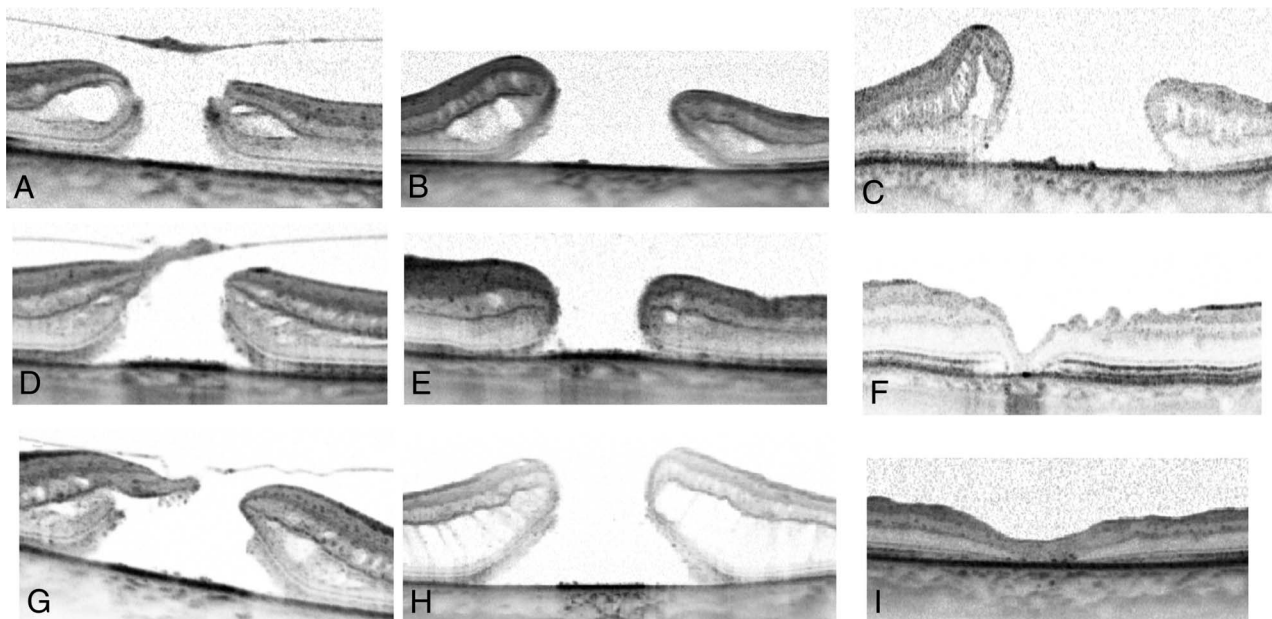


Fig. 1. A 72-year-old woman who had an MH 541 μm in diameter and a visual acuity of 20/400 (A), whose MH enlarged to 1,584 μm after the initial surgery with a reduction of visual acuity to counting fingers (B). The patient was reoperated after 3.5 months, but 14 months later, the MH still persisted and enlarged to 2,265 μm in diameter, with a final visual acuity of counting fingers (C). A 76-year-old woman who had an MH 994 μm in diameter and a visual acuity of 20/100 (D), whose MH diameter had reduced postoperatively to 618 μm , whereas visual acuity was 20/200 (E). The patient was reoperated after 3 months and MH closure was achieved. Eight months later, optical coherence tomography demonstrates irregular retinal contour and significant disturbance of the outer layers, with a final visual acuity of 20/100 (F). A 69-year-old man who had an MH 1,141 μm in diameter and a visual acuity of 20/240 (G), whose MH increased to 1,584 μm after the initial surgery with a reduction of visual acuity to 20/400 (H). The patient was reoperated after 3 months and MH closure was achieved. Seven months later, optical coherence tomography demonstrates mild disturbance of the outer layers, and the final visual acuity had improved to 20/100 (I).

Sourasky Medical Center and the Sheba Medical Center, were retrospectively reviewed. All patients who underwent repeated PPV with gas tamponade for persistent idiopathic MH from January 1, 2006 to June 31, 2011, and had at least 4 months of follow-up were included in the study series. Patients who underwent

silicone oil tamponade for MH closure or who were reoperated for a recurrent MH after anatomical closure in the first procedure were not included. Patients who had previously undergone vitrectomy for any other indication other than the initial MH or any other ocular surgery except cataract extraction were excluded.

The data were retrieved from the medical notes before the surgeries, the two surgical reports, the inpatient department charts, and the outpatient clinic charts. The parameters recorded included demographic information, history of any other ocular conditions, length of visual symptoms before the first surgery, visual acuity and intraocular pressure before the first and second surgeries, MH diameter as documented by optical coherence tomography before and after both surgical procedures and throughout the follow-up, details of the both vitrectomies, interoperative time between surgeries, final visual acuity and intraocular pressure, length of follow-up, occurrence of any postoperative complications, or MH recurrence.

Optical coherence tomography obtained before 2009 was performed by a time domain instrument (Stratus; Carl Zeiss Meditec AG, Jena, Germany) and from 2009 by a spectral domain instrument (Spectralis; Heidelberg Engineering, Inc, Heidelberg, Germany). Macular hole diameter was measured at the base

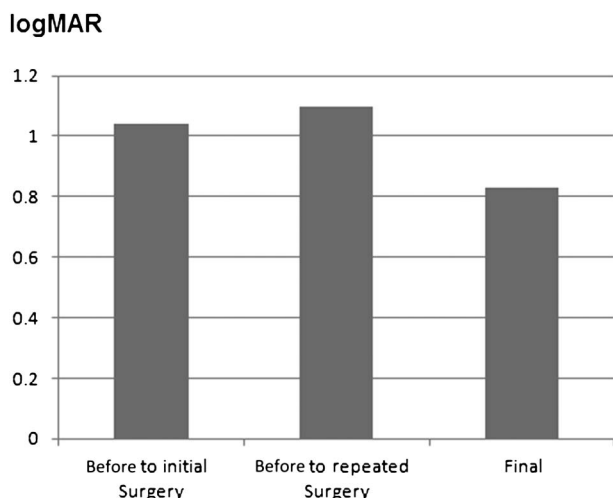


Fig. 2. Mean visual acuity before the initial surgery, the repeated surgery, and at the final examination. The final visual acuity was significantly better than that before the second surgery ($P < 0.001$).

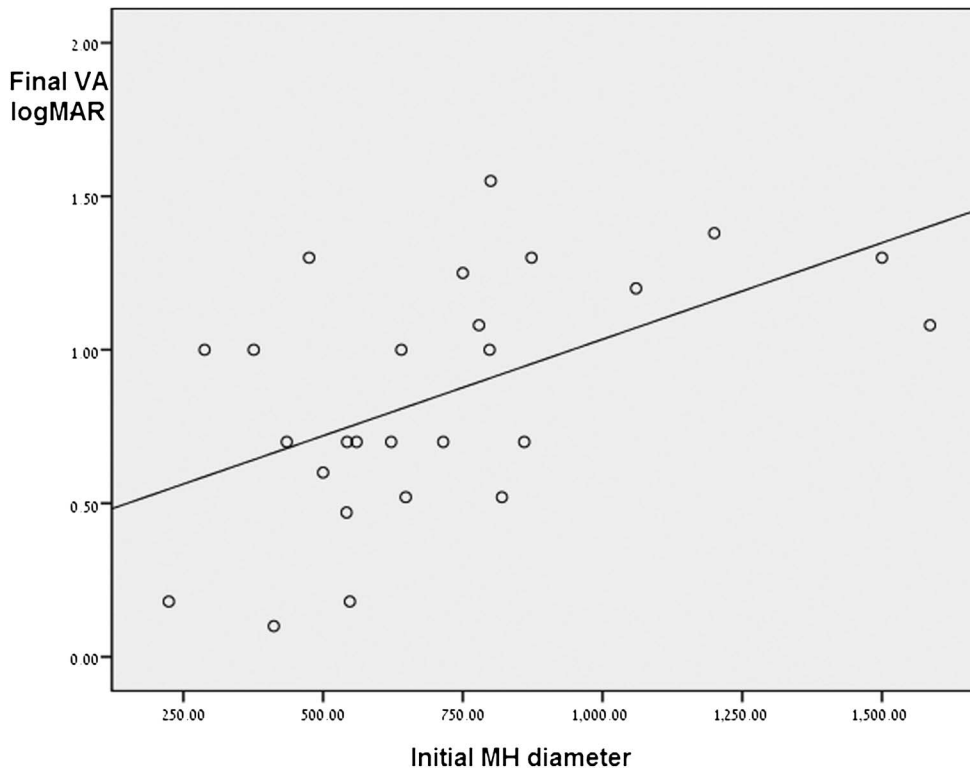


Fig. 3. A significant correlation was demonstrated between smaller initial MH diameter (in μm) and better final visual acuity (in logMAR) ($P = 0.005$).

of the MH, and measurements were made using Image J software, version 1.43u, a Java-based image processing program developed by the National Institute of Health (<http://rsb.info.nih.gov/ij>). The largest measured MH diameter was recorded from each scan. The change in MH diameter between the initial MH and the persistent one after the first surgery was calculated, and the final macular structure was evaluated and categorized as MH closure or persistence. Optical coherence tomography was also analyzed for macular status of the fellow eye of each patient.

The surgical procedures in this study were performed by four surgeons using similar technique. The initial surgery consisted of three-port PPV with induction of posterior vitreous detachment. In 25 cases (86.2%), the ILM was peeled after staining with indocyanine green. In four eyes, the ILM was not peeled because of the surgeon's decision at the time of surgery. These 4 eyes were operated in 2006, and at that time, the ILM was not routinely peeled in all MH cases by all of the surgeons included in this study. All procedures included nonexpansile gas tamponade with either C3F8 16% or SF6 20%. The patients were then instructed to maintain a facedown position for 1 week postoperatively. No conditions limiting the maintenance of this position or failure to comply with it were documented for any of the patients. Prophylactic peripheral 360° endolaser was performed in 12 cases

(41.3%), at the surgeons' discretion. In the second procedure, a 3-port PPV was performed, and the ILM was stained with indocyanine green in 26 eyes (89.6%). In 22 eyes, the ILM was peeled beyond the area that was peeled in the first operation, and in 4 eyes, it was peeled for the first time.

For statistical analysis, all visual acuity values were converted to the logarithm of the minimum angle of resolution (logMAR) scale. According to Holladay¹⁹ and the University of Freiburg study group results,²⁰ blindness was set at 0.00125/2.9 (decimal/logMAR), light perception at 0.0025/2.6, hand movements at 0.005/2.3, and counting fingers at 0.014/1.85.

Correlations between continuous variables were analyzed using the Pearson correlation coefficient and linear regression, and *t*-tests were used to analyze associations between categorical parameters. Data were analyzed using SPSS for windows version 17. A *P* of 0.05 was used to declare statistically significant difference between groups.

Results

Our series includes 29 eyes of 29 patients who met the inclusion criteria. There were 21 women (72.4%) and 8 men (27.6%), with a mean age of 68.9 ± 6.2 years (range, 55–79 years). Twenty-six patients

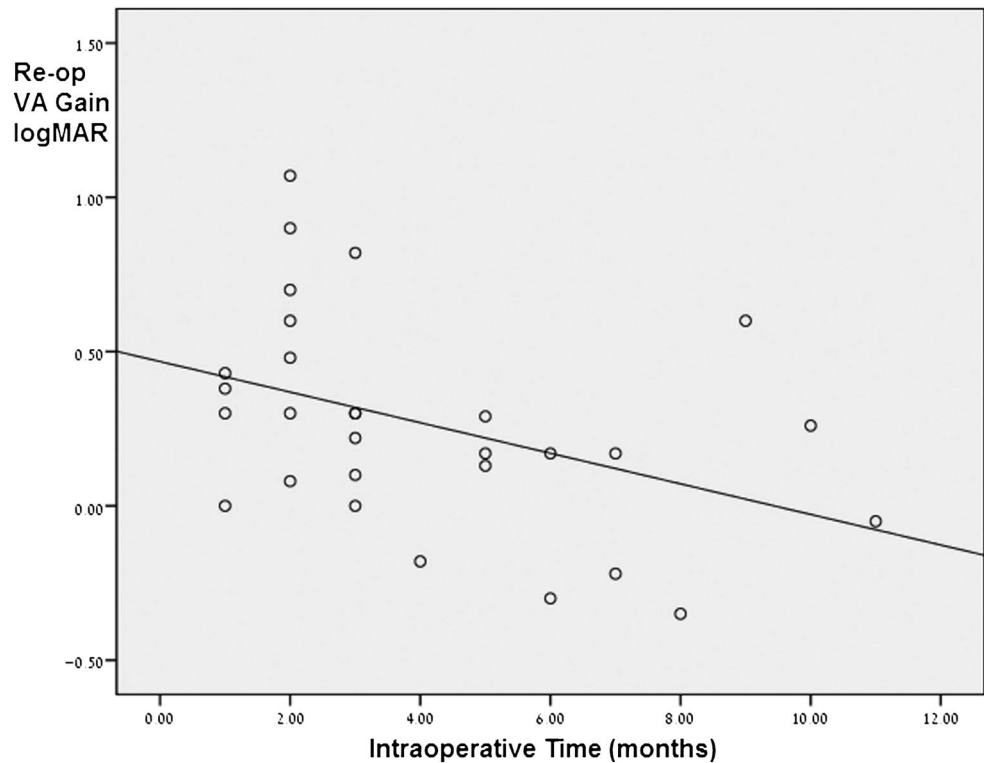


Fig. 4. A significant correlation was demonstrated between shorter intraoperative time (in months) and greater improvement in visual acuity from before the repeated surgery and the final visual acuity ($P = 0.029$). The y-axis presents the logMAR value of the difference in visual acuity between before the second surgery and the final visual acuity (positive values indicate improvement and negative values indicate deterioration of visual acuity).

(89.6%) had no significant other ocular pathology, and the remaining 3 patients included 1 with mild nonproliferative diabetic retinopathy, 1 with intermediate non-neovascular age-related macular degeneration, and 1 with early glaucoma.

No complications were recorded after the initial surgery. Complications after the second surgery included a mild postoperative vitreal hemorrhage in 1 eye (3.4%), with spontaneous clearing over 6 weeks, and elevated intraocular pressure in 1 eye (3.4%), which was managed by topical therapy alone.

At baseline, 24 eyes (82.7%) were phakic and 5 eyes (17.3%) were pseudophakic. Cataract extraction was combined with the initial surgery in 6 eyes and with the second surgery in 12 eyes. Three more patients underwent cataract extraction after both surgeries, and at the final follow-up, 26 eyes (89.6%) were pseudophakic and only 3 eyes (9.4%) were phakic. All pseudophakic eyes had posterior chamber intraocular lenses placed within the capsular bag.

The length of reported visual symptoms before the initial operation was noted for 25 patients (86.2%), and was 8.8 ± 6.8 months (range, 1–24 months). The mean time to the second vitrectomy was 4.1 ± 2.8 months (range, 1–11 months). The mean follow-up time after the second surgery was 12.9 ± 10 months (range, 4–49 months).

Anatomical Results

The initial presentation of the MHs were staged according to the classic classification by Gass^{21,22} and included 14 Stage 4 MHs (48.3%), 12 Stage 3 MHs (41.3%), and 3 Stage 2 MHs (9.4%). The mean size of the hole was $713 \pm 331 \mu\text{m}$ before the first surgery and $801 \pm 390 \mu\text{m}$ before the second surgery, and the difference was not statistically significant ($P = 0.16$).

Anatomical closure of MH was achieved in 20 patients (68.9%) after the second surgery. None of these eyes had recurrence of MH by the end of follow-up. Optical coherence tomography in these eyes demonstrated variable degrees of disturbance in the retinal structure. Examples of the final retinal architecture demonstrating the range of variability between patients with closed MH are presented in Figure 1. Nine eyes (31.1%) had persistent MH after the second vitrectomy.

The mean initial MH diameter (before the first vitrectomy) in patients who achieved closure of the persistent hole was $605 \mu\text{m}$, and $917 \mu\text{m}$ in those who did not. This difference did not achieve statistical significance, but a trend was noted favoring anatomical MH closure in eyes with smaller initial MH diameter (t -test, $P = 0.072$). Patients who achieved anatomical closure were also slightly younger than those who did not (mean ages of 67.5 and 72.1 years, respectively),

and a trend was noted favoring MH closure with younger age (*t*-test, $P = 0.066$). None of the other recorded demographic or surgical parameters were correlated with MH closure. Initial MH grade also did not correlate with MH closure.

A full-thickness MH was documented by optical coherence tomography in 6 (20.6%) of the fellow eyes, and a lamellar hole was documented in 2 eyes (6.9%).

Functional Results

The mean initial visual acuity was 1.04 ± 0.44 logMAR ($\sim 20/220$), mean visual acuity before the second surgery was 1.1 ± 0.31 logMAR ($\sim 20/250$), and mean final visual acuity was 0.83 ± 0.4 logMAR ($\sim 20/135$). The final visual acuity was better than the initial visual acuity, but this difference did not reach statistical significance (*t*-test, $P = 0.06$). However, the final visual acuity had improved significantly when compared with the visual acuity before the second surgery for persistent MH (*t*-test, $P < 0.001$) (Figure 2). Eighteen patients (62%) gained >2 lines of vision after the second surgery. In 3 of these patients, visual acuity improved despite MH persistence, although it should be noted that the improvement was small (1–2 lines) and accompanied by a slight reduction in MH diameter (83–200 μm).

The mean final visual acuity in eyes with closure of the MH was 0.68 ± 0.37 logMAR ($\sim 20/95$), significantly better than that in eyes with failure to close (1.17 ± 0.25 logMAR, $\sim 20/290$, *t*-test, $P = 0.002$). Better final visual acuity was significantly correlated with smaller MH diameter before the initial surgery (regression analysis, $P = 0.005$) (Figure 3). No correlation was found between the final visual acuity and the MH diameter before the second surgery. A larger improvement in visual acuity from the visual acuity before the second surgery to the final visual acuity was correlated with a shorter period of time between surgeries (regression analysis, $P = 0.029$) (Figure 4).

None of the other recorded parameters were correlated with the final visual acuity or with improvement in visual acuity.

Discussion

In this study, an anatomical closure rate of 68.9% was achieved for persistent MHs that were treated by a second vitrectomy. Hillenkamp et al¹⁷ reported a series of 28 eyes with persistent MH, in which the ILM was not peeled initially but was peeled at the repeated surgery, with an anatomical closure rate of 68%. In a subset of 21 eyes with persistent MH reported by D'Souza et al,¹⁸ who underwent initial

PPV with ILM peeling and repeated PPV with extended re-peeling of the ILM, an anatomical closure rate of 52% was achieved. The higher rate of anatomical closure reported by Hillenkamp et al¹⁷ was attributed to the ILM peeling, which has been previously established as a factor promoting MH closure.^{3–7} The lower rate reported by D'Souza et al¹⁸ was attributed to the fact that the ILM had already been peeled during the initial surgery. However, repeated surgery with re-peeling of the ILM was shown to be effective in achieving anatomical closure in a majority of eyes with persistent MHs.¹⁸ Our results further strengthen this finding and demonstrate that repeated PPV with ILM peeling and gas tamponade has a rate of 68.9% for anatomical closure in such eyes. These results are close to those described for reoperation with heavy silicone oil,^{14–16} using a simpler technique with which most vitreoretinal surgeons are familiar, and without exposing the patients to the possible complications associated with silicone oil or to an additional surgery for its removal. We therefore propose that in patients where the MH fails to close after the initial procedure, a second PPV with ILM peeling and gas tamponade should be performed. Such management is likely to result in significant visual improvement, and more complicated procedures can be avoided.

None of the demographic or surgical parameters were correlated with anatomical closure of persistent MHs. Macular hole diameter before the initial or repeated surgery or the change in MH diameter between surgeries did not correlate with anatomical closure, in accordance with previous publications.^{17,18} However, a trend was noted for a smaller initial MH diameter and an increased rate of closure ($P = 0.072$) and for younger age and successful MH closure ($P = 0.066$).

In our series of eyes with persistent MH, visual acuity decreased after the first surgery, but the difference was not statistically significant. In contrast, a significant improvement in the final visual acuity was observed after the second surgery ($P < 0.001$) (Figure 2). Eighteen eyes (62%) gained 2 or more lines after the second surgery. These results are better than that previously reported.^{17,18}

D'Souza et al¹⁸ also found that the final visual acuity was significantly better than that before the repeated surgery but not statistically different from that before the initial surgery. Our results support this and indicate that repeated surgery is warranted from the functional perspective, as it is capable of preventing further visual loss associated with persistence of MH. Although disturbances of the retinal architecture were observed in optical coherence tomography after MH closure in most eyes, the visual acuity had significantly

improved. Evidently, even partial restoration of the retinal layers after closure of the hole is associated with better vision, and almost normal retinal structure is rarely observed after two surgeries for MH.

Better final visual acuity was significantly correlated with smaller initial MH diameter ($P = 0.005$) (Figure 3) and with shorter time between the 2 vitrectomies ($P = 0.029$). These correlations are probably the result of a more extensive damage to the macular structure associated with large holes and more chronic persistent holes. The correlation with shorter interoperative time has not been reported previously.

Twenty-one phakic patients (87.5%) underwent cataract extraction during the follow-up, making cataract the most significant complication in our series. However, this is to be expected in patients with advanced age who undergo two vitrectomies. There were no cases of retinal detachment or endophthalmitis.

Limitations of this study include its small size and retrospective nature. However, it is among the largest series dealing with persistent MHs. Of note is the fact that ILM was peeled in almost all eyes (25 of the 29, 86.2%) at the initial surgery and 26 of the 29 eyes (89.6%) in the second surgery; therefore, no valid comparison with surgeries without ILM peeling was possible. It should also be noted that closure of MH after repeated surgery may not be attributed solely to extended peeling of the ILM, and other factors such as the gas tamponade, careful drainage of fluid over the MH, or postoperative posture may contribute to it. The study cannot differentiate between these factors and does not provide information regarding the effect of length of postoperative posturing and anatomical or functional results. However, we point out that all four eyes in which the ILM was not peeled initially underwent ILM peeling at the second procedure and subsequently closed. This finding strengthens the current concept that ILM peeling improves MH anatomical closure rates.

In conclusion, our results indicate that repeated PPV with ILM peeling and gas tamponade is a safe and effective treatment of persistent MHs. We demonstrate a relatively high rate of success for anatomical closure, along with a significant improvement in visual acuity. Younger patients and those with smaller initial MH diameter may have an increased rate of MH closure after repeated surgery. The final visual acuity in eyes with closed MHs was not significantly better than that before the initial surgery but was significantly better than that before the second surgery, with only minimal postoperative complications. We also found a correlation between earlier reoperation and greater visual

gain. Based on our results, we advocate repeated surgery in all eyes with persistent MH, with a repeated PPV with ILM peeling and gas tamponade as the procedure of choice, and recommend that surgery should not be delayed after the initial failure to close the hole.

Key words: macular hole, persistent macular hole, vitrectomy, reoperation, internal limiting membrane peeling, gas tamponade.

References

1. Kelly NE, Wendel RT. Vitreous surgery for idiopathic macular holes. *Arch Ophthalmol* 1991;109:654–659.
2. Wendel RT, Patel AC, Kelly NE, et al. Vitreous surgery for macular holes. *Ophthalmology* 1993;100:1671–1676.
3. Thompson JT. The effect of internal limiting membrane removal and indocyanine green on the success of macular hole surgery. *Trans Am Ophthalmol Soc* 2007;105:198–206.
4. Brooks HL. Macular hole surgery with and without internal limiting membrane peeling. *Ophthalmology* 2000;107:1939–1948.
5. Christensen UC, Kroyer K, Sander B, et al. Value of internal limiting membrane peeling in surgery for idiopathic macular hole stage 2 and 3: a randomised clinical trial. *Br J Ophthalmol* 2009;93:1005–1015.
6. Kwok AK, Lai TY, Wong VW. Idiopathic macular hole surgery in Chinese patients: a randomised study to compare indocyanine green-assisted internal limiting membrane peeling with no internal limiting membrane peeling. *Hong Kong Med J* 2005;11:259–266.
7. Lois N, Burr J, Norrie J, et al. Internal limiting membrane peeling versus no peeling for idiopathic full thickness macular hole: a pragmatic randomised controlled trial. *Invest Ophthalmol Vis Sci* 2011;52:1586–1592.
8. Williams GA. Macular holes: the latest in current management. *Retina* 2006;26:S9–S12.
9. Haritoglou C, et al. Long-term follow-up after macular hole surgery with internal limiting membrane peeling. *Am J Ophthalmol* 2002;134:661–666.
10. Benson WE, et al. Surgical management of macular holes: a report by the American Academy of Ophthalmology. *Ophthalmology* 2001;108:1328–1335.
11. Ko TH, et al. Ultra-high resolution optical coherence tomography of surgically closed macular holes. *Arch Ophthalmol* 2006;124:827–836.
12. Richter-Mueksch S, et al. Visual performance 3 years after successful macular hole surgery. *Br J Ophthalmol* 2009;93:660–663.
13. Rizzo S, Belting C, Genovesi-Ebert F, et al. Successful treatment of persistent macular holes using “heavy silicone oil” as intraocular tamponade. *Retina* 2006;26:905–908.
14. Rizzo S, Genovesi-Ebert F, Vento A, et al. Heavy silicone oil (Densiron-68) for the treatment of persistent macular holes: Densiron-68 endotamponade for persistent macular holes. *Graefes Arch Clin Exp Ophthalmol* 2009;247:1471–1476.
15. Lappas A, Foerster AM, Kirchoff B. Use of heavy silicone oil (Densiron-68) in the treatment of persistent macular holes. *Acta Ophthalmol* 2009;87:866–870.
16. Oliver A, Wojcik EJ. Macular detachment for treatment of persistent macular hole. *Ophthalmic Surg Lasers Imaging* 2011;42:516–518.

17. Hillenkamp J, Kraus J, Framme C, et al. Retreatment of full-thickness macular hole: predictive value of optical coherence tomography. *Br J Ophthalmol* 2007;91:1445–1449.
18. D'Souza MJJ, Chaudhary V, Devenyi R, et al. Re-operation of idiopathic full-thickness macular holes after initial surgery with internal limiting membrane peel. *Br J Ophthalmol* 2011;95:1564–1567.
19. Holladay JT. Proper method for calculating average visual acuity. *J Refract Surg* 1997;13:388–391.
20. Schulze-Bonsel K, Feltgen N, Burau H, et al. Visual acuities “hand motion” and “counting fingers” can be quantified with the Freiburger visual acuity test. *Invest Ophthalmol Vis Sci* 2006;47:1236–1240.
21. Gass JD. Idiopathic senile macular hole. Its early stages and pathogenesis. *Arch Ophthalmol* 1988;106:629–639.
22. Gass JD. Reappraisal of biomicroscopic classification of stages of development of a macular hole. *Am J Ophthalmol* 1995;119:752–759.