

Surgical Technique

Autologous Neurosensory Retinal Free Flap for Closure of Refractory Myopic Macular Holes

Dilraj S. Grewal, MD; Tamer H. Mahmoud, MD, PhD

Macular holes (MHs) in highly myopic patients often develop at a younger age and may be associated with foveoschisis and a posterior retinal detachment (RD), which portend a poorer prognosis. Although recent anatomical success following primary pars plana vitrectomy (PPV) and internal limiting membrane (ILM) peel with gas tamponade have

+
Video at
jamaophthalmology.com

improved to 60% to 100%, closure rates are significantly lower if associated with foveoschisis or RD, the MH may attain a flat-open configuration even following retinal reattachment, and reopening rates are higher.^{1,2}

Early treatment reports described perifoveolar laser photocoagulation to form chorioretinal adhesions resulting in permanent photoreceptor loss.³ Several procedures are now available for primary repair of myopic MH and MH RD including PPV with ILM peel and gas or silicone oil tamponade, inverted ILM flaps,^{4,5} episcleral posterior buckling, adjuvant blood components,⁶ suprachoroidal buckling, and scleral shortening techniques.⁷ However, options for patients whose MHs fail to close despite initial PPV and ILM peel are limited. Techniques described recently include temporal scleral imbrication,⁸ autologous ILM flap,⁵ addition of autologous blood to the autologous ILM flap,⁹ and autologous anterior or posterior lens capsule flap as a scaffold to plug the MH.¹⁰

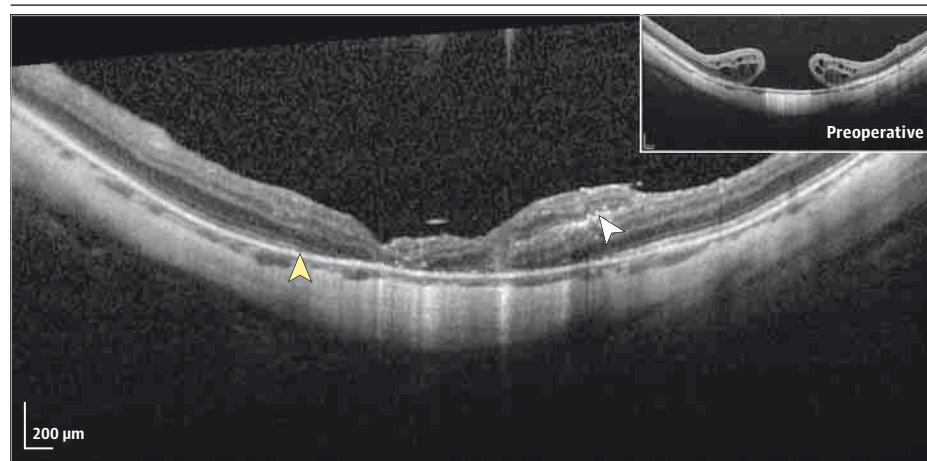
We describe a new technique involving the use of an autologous neurosensory retinal free flap for closure of refractory myopic MHs with associated foveoschisis and/or RD. This technique involves harvesting an autologous neurosensory retinal free flap and positioning it over the refractory MH to provide a scaffold and plug for hole closure.

Surgical Technique

A woman in her 50s, with -15-diopter myopia, had undergone a PPV with ILM peel for MH 6 months prior that was complicated by a refractory MH and the development of RD postoperatively. She subsequently underwent a scleral buckle and PPV for RD repair with silicone oil endotamponade. Silicone oil was removed 3 months postoperatively and she had a persistent 1100- μ m MH (Figure, inset) with corrected visual acuity of 20/200. The fellow eye had myopic foveoschisis without an MH. Surgery was undertaken using peribulbar anesthesia with 23-gauge vitrectomy (Constellation; Alcon). There was poor staining using indocyanine green in the staphyloma but an adequate peel was confirmed by the ILM remnant in the macula. Additional ILM for use as an autologous flap could not be harvested. As she was pseudophakic with an open posterior capsule following a Yag capsulotomy, no lens capsule could be harvested.

A neurosensory retina harvest site was selected superior to the superotemporal arcade. Endolaser barricade was applied in a circular manner around a 2-disc diameter area of retina followed by endodiathermy to blood vessels at the site edges. Using a bimanual approach under chandelier illumination, the edge of the graft was held using forceps and cut using vertical scissors. A 2-disc diameter full-thickness neurosensory retinal free flap was obtained and gently moved toward the MH. Diathermy marks at the edges and pattern of retinal vessels served as anatomical markers to maintain correct orientation of the retinal free flap. Perfluoro-*n*-octane heavy liquid (PFC) (Perfluoron; Alcon) was instilled over the retinal flap. Flap edges were gently flattened and it was stretched to lay flat and cover the entirety of the hole (Video). Direct PFC-silicone oil (1000 centistokes) exchange was performed. Using active aspiration, a few

Figure. Spectral-Domain Optical Coherence Tomography (OCT) Scan



Preoperative OCT shows a refractory 1100- μ m full-thickness macular hole (inset) and postoperative OCT shows macular hole closure with overlying neurosensory retinal free flap (white arrowhead) with partial outer retinal band restoration postoperatively (yellow arrowhead).

bubbles of PFC were removed from the flap edges. The patient was positioned face down postoperatively for 1 week.

The 1-week postoperative optical coherence tomography showed MH closure with the flap visualized as a distinct hyperreflective layer (Figure, white arrowhead) that was stable at 1 month and 3 months. Her visual acuity gradually improved to 20/160 at 1 week and 20/80 at 3 months postoperatively. She reported improvement in distortion and scotoma size. The graft retinotomy site was stable with flat edges on optical coherence tomography. Fundus autofluorescence showed mild hypoautofluorescence corresponding to the flap with gradual improvement. Microperimetry (MAIA; CenterVue) demonstrated improvement in mean retinal sensitivity from 7.5 dB at 1 week to 12.3 dB at 3 months postoperatively with progressive reduction of absolute scotoma. Silicone oil removal was planned at 4 months postoperatively.

Discussion

Surgical options for refractory myopic MH are limited and although visual results may be poor despite successful anatomical closure in myopic MH because of several factors including chorioretinal atrophy, anatomical closure reduces the risk of progression to RD. Inverted ILM flaps, while successful for primary repair of myopic MH, cannot be applied to MHs that have failed to close despite initial PPV and ILM peel. Improved outcomes have been described with autologous ILM flaps. However, harvesting ILM tissue for an autologous flap in the peripheral macula is challenging in myopic MH because of the often concomitant posterior staphyloma, chorioretinal atrophy, and poor staining of ILM.^{5,9} In addition, the fragile nature of the ILM in such eyes makes repositioning an autologous flap within the MH a challenging maneuver. Retaining the autologous flap within the MH is also difficult with loss of flap often reported during fluid-air exchange or with the fluid currents. The lens capsule, recently described as an alternative tissue scaffold, cannot be used in pseudophakic eyes with an open posterior capsule.¹⁰

In contrast to an ILM flap or a lens capsule flap, which often has to be mechanically positioned inside the MH with the potential for

iatrogenic trauma, the neurosensory retinal flap is a thicker, sturdier tissue and can be positioned on the surface of the MH thereby minimizing potential trauma.

Although the exact mechanism remains unknown, inverted and autologous ILM flaps are thought to act as a scaffold for the proliferation of glial cells thus allowing closure of MH. We similarly hypothesize that the neurosensory retinal free flap first serves as a scaffold and second, by secluding communication between the vitreous and subretinal space, forms a macular plug to seal the MH, allowing the subretinal fluid to be gradually removed by the retinal pigment epithelium pump. We believe that the retinal free flap should be more than 0.5 disc diameters larger than the MH to allow for appropriate handling and flap positioning and permit MH closure despite some flap decentration postoperatively.

The midperipheral retinotomy harvest site remained closed with no adjacent epiretinal membrane or RD and the patient did not subjectively notice a corresponding scotoma postoperatively. The increase in retinal sensitivity with corresponding improvement in visual acuity suggests the autologous neurosensory retinal flap may potentially maintain retinal function, although longer follow-up and additional cases are needed to establish its role in possible functional recovery. Gradual restoration of the nasal external limiting membrane and ellipsoid zone was noted suggesting some potential for outer retinal restoration at the graft edges (Figure, yellow arrowhead).

Limitations of this technique include limited follow-up to date on a limited number of cases and unknown potential long-term complications. Long-term results and further evaluation of appropriate size of retinal free flap and potential use of alternative tissue sources as scaffolds will help further refine this technique. Awareness of this technique among general ophthalmologists could potentially facilitate appropriate referrals for such patients who previously did not have surgical options available. While acknowledging these limitations, autologous neurosensory retinal free flap adds to the surgical armamentarium for such challenging cases of myopic MH, refractory to prior surgeries.

ARTICLE INFORMATION

Author Affiliations: Duke Eye Center, Department of Ophthalmology, Duke University Medical Center, Durham, North Carolina.

Corresponding Author: Tamer H. Mahmoud, MD, PhD, Duke Eye Center, Department of Ophthalmology, Duke University Medical Center, 2351 Erwin Rd, PO Box 3802, Durham, NC 27710 (tamer.mahmoud@dm.duke.edu).

Published Online: December 30, 2015.
doi:10.1001/jamaophthalmol.2015.5237.

Conflict of Interest Disclosures: All authors have completed and submitted the ICMJE Form for Disclosure of Potential Conflicts of Interest. Dr Mahmoud reports participation on advisory boards for Dutch Ophthalmic, Alcon, Alimera, and Allergan. No other disclosures were reported.

Funding/Support: This work was supported by the Heed Ophthalmic Foundation and the Ronald G. Michels Fellowship Foundation (Dr Grewal).

Role of the Funder/Sponsor: The funders had no role in the design and conduct of the study; collection, management, analysis, and

interpretation of the data; preparation, review, or approval of the manuscript; and decision to submit the manuscript for publication.

REFERENCES

- Lim LS, Tsai A, Wong D, et al. Prognostic factor analysis of vitrectomy for retinal detachment associated with myopic macular holes. *Ophthalmology*. 2014;121(1):305-310.
- Seike C, Kusaka S, Sakagami K, Ohashi Y. Reopening of macular holes in highly myopic eyes with retinal detachments. *Retina*. 1997;17(1):2-6.
- Harris MJ, de Bustros S, Michels RG. Treatment of retinal detachments due to macular holes. *Retina*. 1984;4(3):144-147.
- Michalewska Z, Michalewski J, Dulczewska-Cichecka K, Nawrocki J. Inverted internal limiting membrane flap technique for surgical repair of myopic macular holes. *Retina*. 2014;34(4):664-669.
- Morizane Y, Shiraga F, Kimura S, et al. Autologous transplantation of the internal limiting membrane for refractory macular holes. *Am J Ophthalmol*. 2014;157(4):861-869.e1.
- Lai CC, Hwang YS, Liu L, et al. Blood-assisted internal limiting membrane peeling for macular hole repair. *Ophthalmology*. 2009;116(8):1525-1530.
- Kono T, Takesue Y, Shiga S. Scleral resection technique combined with vitrectomy for a macular hole retinal detachment in highly myopic eyes. *Ophthalmologica*. 2006;220(3):159-163.
- Fujikawa M, Kawamura H, Kakinoki M, et al. Scleral imbrication combined with vitrectomy and gas tamponade for refractory macular hole retinal detachment associated with high myopia. *Retina*. 2014;34(12):2451-2457.
- Lai CC, Chen YP, Wang NK, et al. Vitrectomy with internal limiting membrane repositioning and autologous blood for macular hole retinal detachment in highly myopic eyes. *Ophthalmology*. 2015;122(9):1889-1898.
- Chen SN, Yang CM. Lens Capsular Flap Transplantation in the Management of Refractory Macular Hole from Multiple Etiologies [published online July 21, 2015]. *Retina*. doi:10.1097/IAE.0000000000000674.